

## ORIGINAL ARTICLE

# Carpal Tunnel Syndrome in Pregnancy : Is There Really Oedema in the Carpal Tunnel?

Mohamed Faizal Sikkandar, Shalimar Abdullah, Rajesh Singh, Parminder Singh Gill, Nur Azuatul Akmal Kamaludin, Tan Jin Aun, Jamari Sapuan

Department of Orthopaedics, Faculty of Medicine, Universiti Kebangsaan Malaysia (UKM), Pusat Perubatan UKM, Jalan Yaakob Latiff, Cheras, Kuala Lumpur. 56000 Malaysia

## ABSTRACT

**Introduction:** Compression of the median nerve in pregnancy is thought to be due to fluid retention within the carpal tunnel space. We aim to discover the cause of carpal tunnel syndrome (CTS) in pregnancy using high resonance ultrasonography. **Methods:** This is a cross-sectional study where obstetric patients were screened for CTS and subjected to a non-invasive ultrasonic imaging. **Results:** A total of 63 patients were seen with 25 diagnosed to have CTS (39.7%) and 38 patients had none (60.3%) based on a screening tool. Age ranged from 20-42 years old with the highest range in the 28-30 year old group (34.9%). In patients with CTS, the cross-sectional area of the median nerve inside the tunnel was a mean of 0.908 cm<sup>2</sup> (ie larger), while non-CTS patients had a mean of 0.797 cm<sup>2</sup> inside the tunnel. The transverse carpal ligament (TCL) measured a mean of 0.0988 cm in the CTS group (ie thinner) and 0.1058 cm in the non-CTS group. Median nerve mobility at equal to or less than one tendon width was 80% in pregnant women with CTS and 92.1% for those without. No fluid was present within the carpal tunnel of all patients. The results were statistically not significant. **Conclusion:** Ultrasonographic evidence in pregnant women with CTS shows a larger median nerve, a more mobile median nerve and a less thick transverse carpal ligament. There is absence of fluid retention and synovitis ruling out extrinsic compression of the median nerve as cause of CTS in pregnancy.

**Keywords:** Entrapment neuropathy, Median nerve, Compression neuropathy, Obstetrics, Ultrasonography

## Corresponding Author:

Shalimar Abdullah, MBBS  
Email: kelapa44@yahoo.com  
Tel: +6012-2240915

## INTRODUCTION

The incidence of carpal tunnel syndrome (CTS) in pregnancy has been reported to be relatively high at 25 percent in a study of 1000 consecutive postpartum patients (1). It has been postulated that the compression of the median nerve and its resulting symptoms in pregnancy is due to either fluid retention or hormone-dependent acute tenosynovitis.

There has been no evidence based study between causal relationship of fluid retention and the occurrence of CTS during pregnancy. On the other hand, no recent literature has described hormone-dependent acute tenosynovitis and its relationship with pregnancy, whether it is causal or just an association. The subsynovial connective tissue (SSCT) connects the carpal tunnel tenosynovium to the flexor tendons and the median nerve (2). The most common histological finding in idiopathic CTS is non-inflammatory fibrosis of the SSCT though this is not proven to occur in pregnant women with median nerve

compression (2).

Imaging modalities such as ultrasonography or magnetic resonance can be effective in indirectly determining median nerve compression at the wrist by defining nerve morphology and anatomic variations eg bifid nerves, persistent median arteries, and palmaris muscles anomalies (3). Ultrasound imaging was chosen in this study as a the tool of choice due to its efficacy as well as practicality in its usage – portability, non-invasiveness, safety and being operator-friendly, considering all these points.

This study therefore aims to elucidate the cause of CTS in pregnancy via imaging study using high resonance ultrasonography. Specifically, we aim to identify via ultrasound, alterations in the carpal tunnel contents causing CTS and correlate it with a validated carpal tunnel severity scoring system.

## MATERIALS AND METHODS

This is a prospective cross-sectional study, conducted over a period of one year in 2015, involving obstetric patients seen in the Obstetrics and Gynaecology Department. A total of 63 patients were included from

a single centre. The inclusion criteria were pregnant women regardless of age and parity, in the third trimester of pregnancy and willing to participate in the study. We selected the third trimester as this was the period where symptoms of CTS were most obvious and evident during pregnancy. Exclusion criteria were patients who do not fall in the above category and patients with higher nerve lesions such as pronator teres syndrome, thoracic outlet syndromes or cervical root impingement (based on history and clinical findings).

All obstetric patients fulfilling the inclusion criteria were interviewed to identify patients having CTS with the 6-item CTS symptoms scale (4). The 6 items are: 1) Pain at night; 2) Pain during the daytime; 3) Numbness and tingling at night; 4) Numbness and tingling during the daytime; 5) Waking up at night with pain in the hand; 6) Waking up at night with numbness and tingling in the hand.

The Boston Carpal Tunnel syndrome questionnaire (BCTQ) was then applied to patients with true CTS to assess severity of their symptoms and their function (5). This questionnaire is a standardized, patient-based outcome measure of symptom severity and functional status in patients with CTS. Patients together with a physician filled up our own questionnaire with general information.

All patients were subjected to a non invasive ultrasonic imaging to assess the space within the carpal tunnel. Patients who have abnormal ultrasound findings such as anatomic variations including bifid nerves, persistent median arteries, and palmaris muscles anomalies such as palmaris profundus and reverse palmaris longus and space occupying lesions were excluded. Scan parameters measured were: i) Cross sectional area of median nerve at pisiform level; ii) TCL width; iii) Ratio of nerve in and out of tunnel; iv) Presence/absence of synovial thickening; v) Presence of synovitis and vi) Nerve mobility.

The ultrasound machine used was a single machine - the Sonosite M-Turbo Ultrasound System by Sonosite Bothell, USA, and was operated by a single operator - the same radiologist for all the patients to eliminate operator-dependent biasness and errors. This results were then validated by an orthopaedic surgeon and tabulated and a comparative analysis was made.

**RESULTS**

Demographic data for ethnicity can be broken down as Malays (81%), Chinese (12.7%), Indians (4.8%) and others (1.6%). The age range was from 20 to 42 years old with the highest range in the 28-30 year old group (34.9%). The commonest presenting age group was within the 28 year old group (Table I).

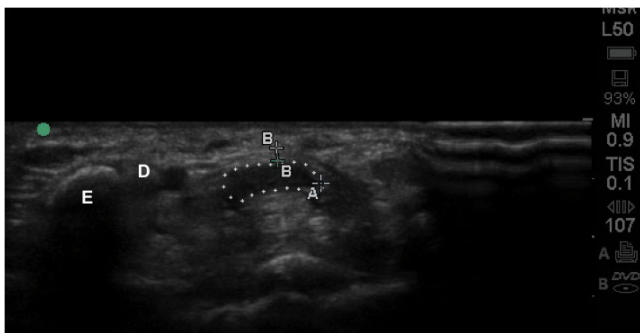
**Table I: Demographic Data**

		n			%		
Age range							
	20-25	6			9.5		
	26-30	30			47.5		
	31-35	18			28.5		
	36-40	7			11.1		
	>40	2			3.2		
Gravida							
	1	20			31.7		
	2	21			33.3		
	3	13			20.3		
	4	7			11.1		
	5	1			1.6		
	6	0			0		
	7	1			1.6		
Parity							
	0	20			31.7		
	1	23			36.5		
	2	12			19.0		
	3	6			9.5		
	4	1			1.6		
	5	0			0		
	6	1			1.6		
	7	0			0		
Diagnosis		Kolmogorov-Smirnov(a)			Shapiro-Wilk		
		Stats	df	Sig.	Stats	df	
Age	CTS	.163	25	.085	.971	25	
	Non-CTS	.128	38	.121	.970	38	
Gravida	CTS	.233	25	.001	.827	25	
	Non-CTS	.222	38	.000	.864	38	
Parity	CTS	.255	25	.000	.803	25	
	Non-CTS	.239	38	.000	.859	38	
<b>Symptom severity scale (n = 25 with CTS)</b>		<b>Mild</b>		<b>Moderate</b>		<b>Severe</b>	
n		19		5		1	
% of all patients		30.2		7.9		1.6	
% of CTS patients		76		20		4	
<b>Disturbance of function (n =25 with CTS)</b>		<b>None (asymptomatic)</b>		<b>Mild</b>		<b>Moderate</b>	
n		14		7		4	
% of all patients		22.2		11.1		6.3	
% of CTS patients		56		28		16	

Of the total 63 patients seen, we diagnosed CTS in 25 of the patients (39.7%) and 38 (60.3%) of them were in the non-CTS group based on the history and physical examination. Out of these 25 patients, surprisingly, only 2 (8%) mentioned their symptoms to the physicians and an overwhelming 23 patients (92%) did not. And in these further two patients, only one was treated and the other was not.

When the Boston Carpal Tunnel Questionnaire was applied on patients with CTS, 76% of respondents claimed to have mild CTS, 20% have moderate CTS and 4% have severe CTS (Table I). The function scores on the other hand saw 56% of patients being asymptomatic, 28% mild, while 16% of patients with CTS in pregnancy scored moderate (Table I).

Fig 1 shows the measured scan parameters: i) Cross sectional area of median nerve at pisiform level; ii) TCL width; iii) Ratio of nerve in and out of tunnel; iv) Presence/absence of synovial thickening; v) Presence of synovitis and vi) Nerve mobility.



**Figure 1: Ultrasonographic findings :** Dotted line represents the median nerve. A = Cross-section of the median nerve (0.18cm<sup>2</sup>); B = Thickness of the transverse carpal ligament (TCL) (0.11cm); C = circumference of the median nerve (1.98cm); D = Guyon's canal; E = Hook of hamate

In the CTS group, the cross sectional area of the median nerve inside the tunnel was a mean of 0.908 cm<sup>2</sup> ie larger, while the non-CTS group had a mean of 0.797 cm<sup>2</sup> inside the tunnel. In all patients, the minimum thickness of the TCL was 0.07 cm and the maximum was 0.15 cm. The mean thickness was 0.1030 cm and the SD was 0.01633. The TCL thickness measured at the level of pisiform bone had a mean of 0.1058 cm in the non CTS group while the CTS group had a mean of 0.0988cm (Table II).

**Table II: TCL (transverse carpal ligament) thickness**

TCL thickness (mm)	7	8	9	10	11	12	13	15	
n	1	10	8	16	13	10	4	1	63
%	1.6	15.9	12.7	25.4	20.6	15.9	6.3	1.6	100

With regards to median nerve mobility within the carpal tunnel: a mobility of less than the one tendon width was found in 36% in the CTS group and 63.2% in the non-CTS group; a mobility equal to one tendon width was found in 44% respondents in the CTS group and 28.9% in the non-CTS group and a mobility of more than one tendon width was found in 20% respondents in the CTS group and 7.9% in the non-CTS group (Table III).

**Table III: Nerve Mobility (Diagnosis Crosstabulation)**

Nerve Mobility	Diagnosis		TOTAL	
	CTS	Non CTS		
< 1 tendon	Count	9	24	33
	% within Nerve Mobility (1 Tendon Width)	27.3%	72.7%	100.0%
	% within Diagnosis	36.0%	63.2%	52.4%
=1 tendon	Count	11	11	22
	% within Nerve Mobility (1 Tendon Width)	50.0%	50.0%	100.0%
	% within Diagnosis	44.0%	28.9%	34.9%
>1 tendon	Count	5	3	8
	% within Nerve Mobility (1 Tendon Width)	62.5%	37.5%	100.0%
	% within Diagnosis	20.0%	7.9%	12.7%
Total	Count	25	38	63
	% within Nerve Mobility	39.7%	60.3%	100.0%
	% within Diagnosis	100.0%	100.0%	100.0%

## DISCUSSION

The prevalence of CTS in pregnant women based on clinical symptoms ranged from 31% to 62% in a systemic review by Padua et al (6). All our patients were symptomatic but only two (8%) out of 63 reported their symptoms to their physician of which only 1 received treatment. Meems study had only 4 out of 219 patients reporting to their physicians (7). Most women experience mild to moderate symptoms. This is the same with our results, where 76% had mild symptoms. Meems et al reasoned that because their symptoms were mild, they were not likely to complain of their symptoms to their physicians. Patient- and doctor-delay is an important issue where women do not report symptoms and physicians do not ask them evidenced with only 25.6% of their patients reporting their symptoms (8).

During pregnancy, changes in hormonal and glucose levels, accumulation of fluid predisposing to oedema and a hypersensitive nerve may lead to carpal tunnel syndrome (CTS) (9,10). Fluid accumulation is within the increased gestational weight gain which also includes increased blood volume, uterine mass, developing fetus and adiposity. Weight gain can be demonstrated with serial measurements but this is more difficult to localise for fluid retention and oedema (11). Voitek et al utilised ring removal as a reflection of oedema and noted rate of ring removal due to swelling was twice greater for symptomatic women with nerve compression symptoms of the hand at 73% than for asymptomatic women at 36% (1). Meems et al also reported that pregnant women with CTS had significantly higher levels of fluid retention (7).

Fluid retention within the carpal tunnel has always been thought to be the cause of median nerve compression in pregnancy. However the most common histological finding in idiopathic CTS is non-inflammatory fibrosis of the pretendinous SSCT (2).

Absence of fluid retention in both groups with reduced thickness of TCL in the CTS group, rules out extrinsic median nerve compression as being a cause of CTS in pregnancy. There is however, evidence of median nerve enlargement occurring during pregnancy, suggesting intrinsic factor as a possible aetiology of CTS in pregnancy. There is a need to further expand and explore this cause, to establish its role as a causal factor.

Median nerve swelling (or cross-sectional area) has a good reliability for a diagnosis of CTS as reported by DeJaco et al (12). Median nerve enlargement (cross-sectional area equal or more than 1cm<sup>2</sup>) at the pisiform level or carpal tunnel inlet has a sensitivity as high as 97.9% for CTS (13). This is very close to our patients with CTS with a mean cross sectional area of the median nerve of 0.908 cm<sup>2</sup>. A more in-depth study reported that the ratio between carpal tunnel inlet and outlet yielded a possibly more accurate assessment (14). These are studies between CTS patients and healthy patients. Ogur et al studied pregnant women with CTS and without and reported a significant difference in median nerve area (15). In our patients with CTS, the cross sectional area of the median nerve inside the tunnel was a mean of 0.908 cm<sup>2</sup> ie larger than the non-CTS patients with a mean of 0.797 cm<sup>2</sup> inside the tunnel.

Additionally, CTS patients have a thicker TCL by 30.9% and a stiffer area at the radial region of the TCL (16). However this finding was not found in our patients. Instead, we found the opposite: the TCL was slightly thicker in the non-CTS group (mean, 0.1058 cm) compared to the CTS group (mean, 0.0988 cm).

Park et al reported a significantly negative correlation between grade of median nerve mobility and severity of CTS using ultrasonographic assessment in non-pregnant women (17). However we found the opposite but it was not statistically significant. Our pregnant women without CTS had a less mobile median nerve compared to those with CTS. The mobility of the median nerve at equal to or less than one tendon width was found in 80% in pregnant women with CTS and in 92.1% of those without CTS. A more mobile median nerve at more than one tendon width mobility was seen in 20% of pregnant women with CTS and only in 7.9% of those without CTS.

Small sample size is one of the limitations of this study. A larger study could have yielded a statistically significant result.

## CONCLUSION

Ultrasonographic evidence in pregnant women with CTS shows a larger median nerve, a more mobile median nerve and a less thick TCL. Absence of fluid retention and synovitis in both groups rules out extrinsic compression of the median nerve as cause of CTS in pregnancy. However, evidence of median nerve enlargement suggests intrinsic factors as a possible aetiology of CTS in pregnancy.

## ACKNOWLEDGMENTS

This study was supported by a grant from the Faculty of Medicine, UKM (P49489 / 2013). Further acknowledgements to Dr Rizwana Iqbal Hussain and Associate Professor Dr Shamsul Azhar Shah..

## REFERENCES

1. Voitek AJ, Mueller JC, Farlinger DE, Johnston RU. Carpal tunnel syndrome in pregnancy. *Can Med Assoc J.* 1983;128(3):277-81.
2. Ettema AM, Belohlavek M, Zhao C, Oh SH, Amadio PC, An K-N. High-resolution ultrasound analysis of subsynovial connective tissue in human cadaver carpal tunnel. *J Orthop Res.* 2006;24(10):2011-20.
3. Spinner RJ, Hйbert Blouin M-N, Amrami KK. Dynamic imaging in patients with carpal tunnel syndrome. *Clin Anat.* 2010;23(3):NA-NA.
4. Atroshi I, Lyrйn P-E, Gummesson C. The 6-item CTS symptoms scale: a brief outcomes measure for carpal tunnel syndrome. *Qual Life Res.* 2009;18(3):347-58.
5. Levine DW, Simmons BP, Koris MJ, et al. A self-administered questionnaire for the assessment of severity of symptoms and functional status in carpal tunnel syndrome. *J Bone Joint Surg Am.* 1993;75(11):1585-92.
6. Padua L, Pasquale A Di, Pazzaglia C, Liotta GA, Librante A, Mondelli M. Systematic review of pregnancy-related carpal tunnel syndrome. *Muscle Nerve.* 2010;42(5):697-702.
7. Meeems M, Truijens SEM, Spek V, Visser LH, Pop VJM. Prevalence, course and determinants of carpal tunnel syndrome symptoms during pregnancy: a prospective study. *BJOG: An Intl J of Obs Gynae.* 2015;122(8):1112-8
8. Sapuan J, Yam KF, Noorman MF, et al. Carpal tunnel syndrome in pregnancy - you need to ask! *Singapore Med J.* 2012;53(10):671-5.
9. Khosrawi S, Maghrouri R. The prevalence and severity of carpal tunnel syndrome during pregnancy. *Adv Biomed Res.* 2012;1:43.
9. Osterman M, Ilyas AM, Matzon JL. Carpal Tunnel Syndrome in Pregnancy. *Orthop Clin North Am.* 2012;43(4):515-20.

10. Zyluk A. Carpal tunnel syndrome in pregnancy: a review. *Polish Orthop Traumatol.* 2013;78:223-27.
11. Wright C, Smith B, Wright S, Weiner M, Wright K, Rubin D. Who develops carpal tunnel syndrome during pregnancy: An analysis of obesity, gestational weight gain, and parity. *Obstet Med.* 2014;7(2):90-94.
12. Dejaco C, Stradner M, Zauner D, et al. Ultrasound for diagnosis of carpal tunnel syndrome: comparison of different methods to determine median nerve volume and value of power Doppler sonography. *Ann Rheum Dis.* 2013;72(12):1934-39.
13. McDonagh C, Alexander M, Kane D. The role of ultrasound in the diagnosis and management of carpal tunnel syndrome: a new paradigm. *Rheumatology.* 2015;54(1):9-19.
14. Fu T, Cao M, Liu F, et al. Carpal tunnel syndrome assessment with ultrasonography: value of inlet-to-outlet median nerve area ratio in patients versus healthy volunteers. *PLoS One.* 2015;10(1):e0116777.
15. Ogur T, Yakut ZI, Teber MA, et al. Ultrasound elastographic evaluation of the median nerve in pregnant women with carpal tunnel syndrome. *Eur Rev Med Pharmacol Sci.* 2015;19(1):23-30.
16. Marquardt TL, Gabra JN, Evans PJ, Seitz WH, Li Z-M, Li Z-M. Thickness and Stiffness Adaptations of the Transverse Carpal Ligament Associated with Carpal Tunnel Syndrome. *J Musculoskelet Res.* 2016;19(4).
17. Park G, Kwon DR, Seok JI, Park D-S, Cho HK. Usefulness of ultrasound assessment of median nerve mobility in carpal tunnel syndrome. *Acta Radiol.* March 2018:028418511876224.