

ORIGINAL ARTICLE

The Leukocyte Profile, Histopathology and Molecularly Characteristics of Rabbits Scabies' From East Java, Indonesia

Nunuk Dyah Retno Lastuti¹, Lucia Tri Suwanti¹, Anwar Ma'ruf¹, Amirotul Azhimah², Putri Pelangi Noor Aina Zahro²

¹ Postgraduate School, Universitas Airlangga, Jl. Airlangga No.4-6 Airlangga Gubeng, Surabaya 60115, Jawa Timur, Indonesia

² Student of Faculty Veterinary Medicine, Universitas Airlangga, Jl. Mulyorejo, Surabaya 60115, Jawa Timur, Indonesia

ABSTRACT

Introduction: Scabies is known as an emerging or re-emerging parasitic disease with the prevalence are very high both in human and animals in the world. This study aims to observe the molecularly characteristic of *Sarcoptes scabiei*, leukocyte profile, and histopathology of rabbits' scabies from Pasuruan and Sidoarjo, East Java, Indonesia. **Methods:** Twelve local rabbits from Pasuruan and Sidoarjo were used as experimental animals infected with *S. scabiei*, aged around 1 year old with specific clinical signs of scabies, and were clustered based on mild, moderate, and severe illness. A blood sample was collected from the auricular vein to measure the number of leukocyte and differential account (eosinophile, neutrophile, and lymphocytes). Skin histology was observed microscopically with Hematoxyline and Eosin (HE) staining. Around 500 mites *S. scabiei* was isolated to detect the COX1 gene from the mitochondria of *S. scabiei* by PCR with primer TCTAGGGGCTGGATTAGTATG-3' and 5'-AGTTCCTCTACCAGTTCAC-3'. **Results:** Histopathological changes of rabbits' skin showed parakeratosis, acanthosis, and change in the dermis with inflammatory cell infiltration, degeneration, and congestion. The PCR product with agarose gel 2% showed that the COX-1 gene in mitochondria of *S. scabiei* isolated from Sidoarjo and Pasuruan has length around 290 bp, and identity > 98% with gen bank data. **Conclusion:** *S. scabiei* was able to increase the leukocyte profile, and it caused histopathology changes. The molecular characterization of the COX-1 gene of mitochondria of *S. scabiei* of rabbits has a length of around 290 bp.

Keywords: *Sarcoptes scabiei*, Leukocyte profile, Histopathology, COX 1, Rabbits

Corresponding Author:

Nunuk Dyah Retno Lastuti, M.S
Email: nunuk_dyah@fkh.unair.ac.id
Tel: +(62) 31 5041566

INTRODUCTION

Scabies is known as an emerging or re-emerging parasitic disease with a very high prevalence both in human and animals in the world, but the controlling program of this disease is limited (1,2). The high prevalence of goat and rabbit scabies in several farms in Indonesia has been reported and it is correlated with a lack of management in hygiene and sanitation (3,4). Pathogenicity of scabies is related to hypersensitivity reaction type IV in human because the mite invades and replicates in the stratum corneum and form a tunnel that causes irritation and itch, followed by scratch that causes edema with dry exudate which later forms a crust on the skin surface. The crust will get thicker, then keratinized, and will cause a proliferation of fibrous tissue (3,5). If the infection has reached the fibrous

tissue followed with fibrosis, hyperplasia epidermis, and increase of mononuclear cells infiltration in perivascular. If that is the case, then it can be concluded that the infection has reached a chronic stadium or dangerous stage (5,6). Protein with a molecule weight 61 kDa and 53 kDa have a role in the pathogenesis of scabies in rabbit (3). In some cases, a severe infection could be followed by secondary infection of other microorganisms, such as *Staphylococcus aureus* and *Streptococcus pyogenes*. Secondary infection can cause eosinophil infiltration which is followed by an increase of Th2 cell, cytokine IL-4, IL-5, and IL-13 (4,7). In this paper, we described leucocytes profile, histopathological changes, and molecularly parasite of rabbits scabies from Pasuruan and Sidoarjo, East Java, Indonesia.

MATERIALS AND METHODS

This research has been approved by the Ethical Committee Faculty of Veterinary Medicine Universitas Airlangga, with license number 630-KE, 2019. Twelve

local rabbits were used as the experimental animals and infected with *S. scabiei*, aged around 1 year old with specific clinical signs of scabies, which are crust, inflammation, and thickness of the skin around the eyes, mouth, ears, feet. The rabbits were from Pasuruan and Sidoarjo, East Java, and they were clustered based on mild, moderate, and severe illness. Scrapping was performed to the rabbits, with the purpose to identify *S. scabiei* based on the morphology. Around 500 mites *S. scabiei* was isolated to detect the COX-1 gene from the mitochondria of *S. scabiei* by PCR with primer TCTTAGGGGCTGGATTAGTATG-3' and 5'-AGTTCCTCTACCAGTTCCAC-3'.

A blood sample was collected from the auricular vein to measure the number of leukocyte and differential account (eosinophile, neutrophile, and lymphocytes). Skin histology was observed microscopically with Hematoxylyne and Eosin (HE) staining. The lesions were assigned by scoring from 0 to 4 (0: not seen; 4: highly visible) on each lesion in terms of parasitic infestation, parakeratosis, acanthosis, cell degeneration, congestion, and inflammation(8).

RESULTS

Leukocytes profile (the number of eosinophile, neutrophile, and lymphocyte) from mild, moderate and severe illness, appeared to be significantly different ($p < 0.05$) (Table. I). The result of the leukocyte profile showed a significant difference ($p < 0.05$) between groups and increase with the severity of the infection. The increasing phenomenon was caused by an allergic reaction in the presence of *S. scabiei* which is related to hypersensitivity reaction type I until IV in humans. Hypersensitivity type IV (delayed-type hypersensitivity) is associated with IL-12 that is produced by macrophage after interaction with microbes and induced mast cell to produce histamine granule that causes inflammation and crust in the skin and affects hair loss (5,9).

Histopathological changes in skin tissue that was infected with scabies from mild, moderate, and severe can be found through the existence of *S. scabiei* mites in the epidermis, present of parakeratosis and acanthosis in the epidermis, and change in the dermis with inflammatory cell infiltration, degeneration, and congestion. Histopathological changes showed a significant difference ($p < 0.05$) between groups. Histopathological change as shown in Fig 1.

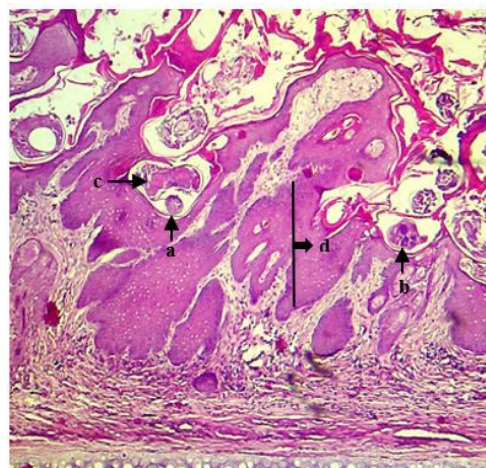


Fig. 1 : Stratum corneum of rabbits infected with *S. scabiei* mites also showed several stadia of the parasite which are (a) egg, (b) larva, (c) adult mite, (d) acanthosis, magnification 40x, Nikon® E-100 Microscope.

DISCUSSION

Sarcoptes scabiei mites were isolated from rabbits in Sidoarjo and Pasuruan, and the DNA was extracted followed by PCR with COX-1 Primer from Chong'qing rabbit (GenBank accession No. EU256388.1). After electrophoresis was done with agarose gel 2%, the PCR product showed that the COX-1 gene in mitochondria of *S. scabiei* isolated from Sidoarjo and Pasuruan has a length of around 290 bp. The result of the research from Lastuti et al. (2019) shows that COX-1 gene in mitochondria of *S. scabiei* infected

Table I : Profile of leucocytes, eosinophils, neutrophils and lymphocytes of rabbits scabies.

Rabbits scabies	Leukocyte (cell/mm ³)	Eosinophil (cell/mm ³)	Neutrophil (cell/mm ³)	Lymphocyte (cell/mm ³)
Control	6930 ^a ± 929	228 ^a ± 85	3659 ^a ± 466	2777 ^a ± 916
Mild	8260 ^b ± 253	462 ^b ± 94	4930 ^b ± 466	3794 ^a ± 723
Moderate	9670 ^c ± 396	619 ^c ± 86	6912 ^c ± 660	5852 ^a ± 22159
Severe	13030 ^d ± 1013	1068 ^d ± 143	9878 ^d ± 879	8414 ^b ± 1479

Note. Different superscripts (a,b,c,d.) on the same column show significant difference ($p < 0.05$).

rabbits which originated from Mojokerto also has a length of 290bp, and matched with the target.

S. scabiei mites originated from rabbits that showed clinical signs of severe scabies, with histopathological changes such as parakeratosis, acanthosis, inflammatory cell infiltration, degeneration, and congestion (5,6). Through histopathological examination, inflammatory cell infiltration was shown, in which it is also connected with the antigen of *S. scabiei* which was able to express some cytokines (IL-6, IL-8, G-CSF, VEGF) in fibroblast and keratinocytes cells. The secretion of cytokine will stimulate eosinophils to secrete granules which cause allergic reactions such as edema, mucus secretion, and leukocyte infiltration (9).

Based on the case reports, the rabbits originated from Sidoarjo and Pasuruan were traditionally kept in a dirty cage with low sanitation and hygiene management. Thus, the transmission of scabies happened in a short time through direct contact. *Sarcoptes scabiei* can live within three weeks (1). According to the examination, the rabbits from the Sidoarjo farm were originated from Pasuruan.

CONCLUSION

Sarcoptes scabiei was able to induce change in the leukocytes profile by increasing the number of leukocyte, eosinophil, neutrophil, and lymphocyte, and it caused parakeratosis and acanthosis in the epidermis, along with infiltration inflammatory cells, degeneration and congestion in the dermis. COX-1 gene of *S. scabiei* that caused scabies of rabbits from Pasuruan and Sidoarjo could be detected by PCR which has a molecular weight of around 290 bp.

ACKNOWLEDGEMENT

The authors are thankful to the Director of Postgraduate School, Universitas Airlangga for research funding that was granted in 2019.

REFERENCES

1. Alasaad S, Rossi L, Heukelbach J, Perez J, Hamarsheh O, Otiende M, et al. The neglected navigating web of the incomprehensibly emerging and re-emerging sarcoptic mite. *Infect Genet Evol.* 2013;17:253–9.
2. Arlian L, Morgan M. A review of *Sarcoptes scabiei*: past, present and future. *Parasites & Vectors.* 2017;10:297.
3. Lastuti N, Hastotetik P, Tri Suwanti L, Chrismanto D. Exploration of *Sarcoptes scabiei* Antigenic Protein Which Play Roles in Scabies Pathogenesis in Goats and Rabbits. *Iran J Parasitol.* 2018;13(3):466–72.
4. Lastuti N, Yuniarti W, Hastutiek P, Suwanti L, Chrismanto D. Humoral and cellular immune response induced by antigenic protein of *Sarcoptes scabiei* var. *caprae*. *Vet World.* 2018;11(6):819–23.
5. Espinosa J, R6ez-Bravo A, Lypez-Olvera J, P6rez J, Lav6n S, Tvarijonaviciute A, et al. Histopathology, microbiology and the inflammatory process associated with *Sarcoptes scabiei* infection in the Iberian ibex, *Capra pyrenaica*. *Parasite and Vectors.* 2017;10: 596.
6. Tarigan S. Histopathological changes in naive and sensitised goats caused by *Sarcoptes scabiei* infestation. *Indones J Anim Vet Sci.* 2003;8(2):114–21.
7. Casais R, Granda V, Balseiro A, Cerro A, Dalt N, Gonz6lez BP, et al. Vaccination of rabbits with immunodominant antigens from *Sarcoptes scabiei* induced high levels of humoral responses and pro-inflammatory cytokines but confers limited protection. *Parasit Vectors.* 2016;9(1):435–342.
8. Klopffleisch R. Multiparametric and semi quantitative scoring systems for the evaluation of mouse model histopathology – a systematic review. *BMC Vet Res.* 2013;9:123.
9. Walton S, Pizzutto S, Slender A, Viberg L, Holt D, Hales B, et al. Increased allergic immune response to *Sarcoptes scabiei* antigens in crusted versus ordinary scabies. *Clin Vaccine Immunol.* 2010;17(9):1428-1438.