

CASE REPORT

Clinical Assessment Limitation in Extragastrointestinal Stromal Tumour of Rectovaginal Septum Diagnosis: A Case Report

Noor Azura Noor Mohamad¹, Kavitha Nagandla², Nirmala Chandraleka Kampan³, Mohamad Nasir Shafiee³

¹ Obstetrics and Gynaecology Department, Faculty of Medicine, Universiti Teknologi MARA, 47000 Sungai Buloh, Selangor, Malaysia

² Obstetrics and Gynaecology Department, International Medical University, 57000 Kuala Lumpur, Federal Territory of Kuala Lumpur, Malaysia

³ Gynaecologic Oncology Unit, Obstetrics and Gynaecology Department, Hospital Canselor Tuanku Muhriz, 56000 Kuala Lumpur, Malaysia

ABSTRACT

Extragastrointestinal tumour of rectovaginal septum (rvGIST) is a rare malignancy that affects rectovaginal septum. We present a case of rvGIST that was initially managed as cervical eGIST based on clinical assessment. A 66-year-old woman presented with postmenopausal bleeding and constipation. Bimanual pelvic examination revealed an irregular mass occupying the vagina. CT thorax, abdomen and pelvis showed a 9.2 x 10.0 x 14.0 cm pelvic mass arising from cervix, extending superiorly to involve the uterus. The patient proceeded to undergo total abdominal hysterectomy, bilateral salpingo-oophorectomy, enucleation of rectovaginal septum mass, rectosigmoidectomy and permanent colostomy. Intraoperatively, there was a 9 x 7 cm mass arising from rectovaginal septum. Histopathological examination of surgical specimen revealed spindle cell tumour diffusely positive for CD34, CD117 and DOG1. The final diagnosis was rvGIST. In conclusion, the diagnosis of rvGIST require a combination of clinical assessment with intraoperative finding and histological assessment of the surgical specimen.

Malaysian Journal of Medicine and Health Sciences (2022) 18(4):224-226. doi:10.47836/mjmhs18.4.31

Keywords: Extragastrointestinal stromal tumour, Rectovaginal septum, Postmenopausal bleeding, Case report

Corresponding Author:

Noor Azura Noor Mohamad; MRCPI, MRCOG

Email: azuranoor@uitm.edu.my

Tel: +6 03 6126 5000

INTRODUCTION

Gastrointestinal stromal tumour (GIST) is soft tissue sarcoma that originates from mesenchyme, and constitute 1% of primary gastrointestinal malignancy (1). All segments of the gastrointestinal tract can be affected by GIST with greater preponderance towards the stomach (60%), small intestine (30%) and large colon (10%) (2). GIST is hypothesised to originate from pacemaker of the intestinal cells namely cells of Cajal which is found in between the muscularis propria (1). Ninety-five percent of GIST shows positive expression for CD117 and CD34; these markers are also used to diagnose extragastrointestinal stromal tumour (eGIST) (2). GIST is distinctive from the other mesenchymal growth as it shows positive immunohistochemistry for DOG1 (Discovered on GIST-1) in 98% of the cases (3). DOG1 expression is independent of the c-kit or platelet-derived growth factor receptor alpha (PDGFRA) gene mutation, and is a reliable marker for GIST in the instance of negative CD117 (3). Table I showed the differential

diagnosis of GIST based on the immunohistochemistry as illustrated by Hirota et al (4). GIST can also occur outside of the alimentary tract, also known as extragastrointestinal stromal tumour (eGIST) (2). eGIST has been reported to occur at the mesentery, omentum, bladder and rectovaginal septum (RVS), to name a few (1). Extragastrointestinal stromal tumour of rectovaginal septum (rvGIST) is diagnosed when GIST occurs at the rectovaginal septum. When GIST occurs outside of the gastrointestinal tract, the tumour is more aggressive as reflected by high mitotic figure of more than 2/50 high power fields. In this case report, we present a case of extragastrointestinal tumour of rectovaginal septum (rvGIST) that was initially managed as cervical eGIST based on clinical assessment.

CASE REPORT

A 66-year-old woman para 9 (all full-term vaginal deliveries) presented with 4-month history of postmenopausal bleeding and constipation. In the past medical history, the patient had poorly controlled diabetes, hypertension and class III obesity. Abdominal palpation showed a pelvic mass of 12 weeks' size. Bimanual pelvic examination revealed an irregular mass occupying the vagina. Normal cervix was not palpable

Table 1: Differential diagnosis of GIST

Differential diagnosis	Cell Type	Immunohistochemistry								
		α -SMA	Desmin	KIT	DOG1	S100 protein	ALK	Nuclear β -catenin	STAT6	CD34
Leiomyoma	Spindle	+	+	-	-	-	-	-	-	+/-
Leiomyosarcoma	Spindle	+	+/-	-	-	-	-	-	-	+/-
Schwannoma	Spindle	-	-	-	-	+	-	-	-	+/-
Desmoid	Spindle/stellate	-	-	-	-	-	-	+	-	-
Inflammatory fibroid polyp	Spindle	+/-	?	-	-	-	-	-	-	+/-
Perivascular epithelial cell tumor	Spindle/epithelial	+		+/-	-	-	-	-	-	
Spindle fibrous tumor	Spindle	?	?	-	-	-	-	-	+	+
Inflammatory myofibroblastic tumor	Inflammatory	+	?	-	-	-	+/-	-	-	?
Globus tumor	Epithelioid	+	-	-	-	-	?	-	-	-

Adapted from Hirota, S. (2018). Differential diagnosis of gastrointestinal stromal tumor by histopathology and immunohistochemistry. *Transl Gastroenterol Hepatol*, 3, 27. doi:10.21037/tgh.2018.04.01

hence no cervical smear was taken. CT thorax, abdomen and pelvis showed a 9.2 x 10.0 x 14.0 cm lobulated midline pelvic mass arising from the cervix and extended superiorly to involve the uterus. Complementary MRI pelvis reported a lobulated heterogenous mass with cystic component and flow void seen at the cervical region measuring 9.1 x 9.9 x 9.3 cm, concluded as a cervical mass involving a third of the lower uterus and upper third of the vagina with poor fat plane with the rectum. Fig. 1 showed the sagittal and coronal view of the tumour on MRI pelvis. Examination under anaesthesia confirmed bimanual pelvic examination finding, and biopsy of the mass occupying the vagina was concluded as cervical eGIST. Cystoscopy showed no tumour invasion into the bladder mucosa. Colonoscopy was performed to find external compression onto the anterior rectal wall caused by a solid mass at 5 cm from the anal verge.

The patient underwent total abdominal hysterectomy and bilateral salpingo-oophorectomy (TAHBSO) which proceeded to enucleation of rectovaginal septum mass, rectosigmoidectomy and permanent colostomy. Intraoperatively, a 9 x 7 cm mass was found bulging into the posterior vaginal wall. Mass enucleation was done through vertical incision on the posterior vaginal wall. However, the tumour capsule was adherent to rectal serosa at its superior part with resultant iatrogenic rectal injury during its resection, requiring rectosigmoidectomy

and permanent colostomy. Histopathological examination of the mass in rectovaginal septum revealed spindle cell tumour arranged in interlacing fascicles to almost diffuse sheets pattern with some areas of herringbone or storiform architecture. Mitotic figures were 65/10 high power fields. Immunohistochemistry showed the spindle cells were diffusely positive with CD34, CD117 and DOG1, and negative for SMA, Desmin, Cyclin D1, CD10, S100, EMA, AE1/AE3, p63 and ER. The uterus, cervix, bilateral fallopian tubes and bilateral ovaries showed no significant pathology. The final diagnosis was extragastrointestinal stromal tumour of rectovaginal septum (rvGIST). Oral imatinib mesylate was to commence at 12 weeks post-surgery but the patient was not able to do so due to financial constraint. The progression-free interval was 5 months, after which the patient reported per vaginal bleeding, and was admitted with symptomatic anaemia. Repeat CT TAP showed tumour recurrence in the pelvis, right hypogastrium, subcutaneous layer at colostomy site, lung and thoracic bone. Palliative radiotherapy was offered but declined by patient. The patient died at 7 months post-surgery due to advanced metastatic disease.

DISCUSSION

Rectovaginal septum (RVS) is a pelvic structure located between posterior vaginal wall and anterior rectal

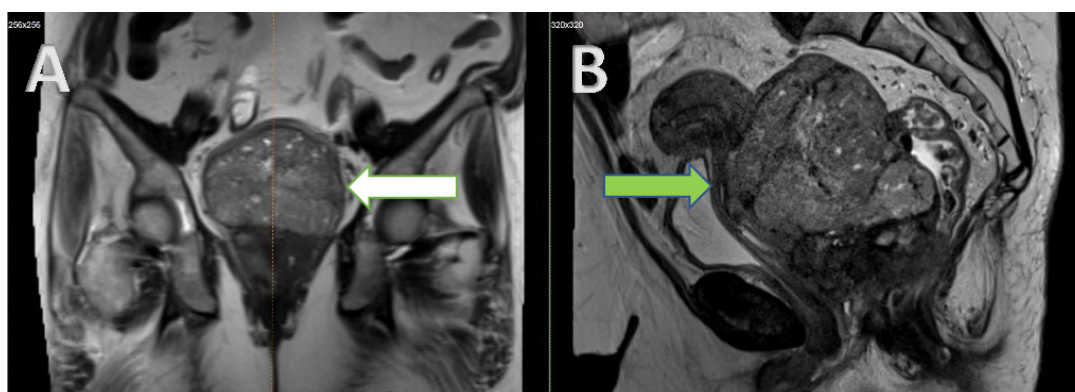


Figure 1: MRI pelvis image, illustrating the cervical eGIST. On the left of the picture labelled as A, the white arrow indicated the cervical mass at coronal view. On the right side of the figure labelled as B, the green arrow referred to the cervical mass at sagittal view.

wall. The septum structural integrity is contributed by its collagen fibre and smooth muscle components, which permits its flexibility to move between the vagina and the rectum (5). It serves as pelvic support and enables the innervation of the pelvic structures via inferior hypogastric plexus (5). The average RVS length is 73 mm, being thinnest at its middle third (2.2 mm) and thickest at its upper third (2.8 mm) (5). rvGIST is a rare type of eGIST. Gynaecological symptoms in rvGIST vary from incidental finding of vaginal tumour at routine pelvic examination, to per vaginal bleeding (1) and bulging vaginal mass (2). Patients with rvGIST also presented with abdominal discomfort (1), and constipation reported in current case. The non-specific symptom caused by rvGIST can be attributed by the fact that the tumour location is in between the gastrointestinal and genitourinary system. Compression effect of rvGIST onto the anterior rectal wall can mimic physiological symptom caused by constipation hence can be overlooked by patient, leading to delayed tumour detection. As the rvGIST mass typically bulge onto the posterior vaginal wall, the vaginal distension may not be noticeable by the patient unless the patient complained of abnormal bleeding from the genital tract, which would then trigger the investigation of the cause of bleeding, as in our case study.

Typically, rvGIST size ranges between 2 to 8 cm (2). The variation of rvGIST size and ability of the RVS to harbour the tumour until larger size is due to the fact that RVS of patient with previous multiple vaginal delivery was found to be significantly greater in length and thickness compared to the nulliparous patient (5). Our patient had 9 full term vaginal deliveries, allowing for the RVS to gain greater length hence delaying the rvGIST detection until it reached 9 cm diameter. The most ideal primary surgery for rvGIST is en bloc resection of the tumour as it allows for inclusion of the healthy surgical margin, and ascertain the true involvement of luminal gastrointestinal tract or mesentery (1). The main issue with radical excision of rvGIST is the subsequent extensive damage to the surrounding tissue especially the reproductive organ (3). In the previous case studies, 16 of the 18 cases including our case were managed with tumour enucleation via vaginal or rectal approach. Hysterectomy was performed in 5 of the cases including our case. There were 2 cases managed with neoadjuvant imatinib mesylate as the primary treatment. As for our patient, the decision to proceed with hysterectomy was based on the clinical diagnosis of cervical eGIST, which would not respond well with primary chemoradiotherapy. Neoadjuvant imatinib mesylate was offered but declined by the patient due to the financial constraint. In our case study, the suspicion for cervical eGIST was not only found from physical examination, rather was supported by radiological

imaging. Such incident has not been encountered in previous case reports.

CONCLUSION

Diagnosis of rvGIST requires a combination of the clinical features, imaging, intraoperative finding and final histology. Relying on clinical assessment alone may result in the patient not being managed with the optimal surgical option, especially when it is known that the surgical margin completeness cannot be achieved due to the size and anatomical location of the tumour. The case report strength is that the diagnosis of eGIST was made from the first biopsy result, unlike the previous reports that missed the eGIST diagnosis and managed as leiomyosarcoma or leiomyoma. The case report limitation is that the case was initially managed as cervical eGIST, of which the mode of treatment is either surgery or chemoradiation therapy, and that the use of neoadjuvant imatinib has not been encountered in the literature for cervical eGIST.

ACKNOWLEDGEMENT

Special thanks to the clinicians looking after the patient during the inpatient care.

REFERENCES

1. Hanayneh W, Starr J, George TJ, Jr., Parekh H. Extragastrintestinal stromal tumors of the pelvic cavity and the vagina: Two case reports and review of the literature. *Gynecol Oncol Rep.* 2018;25:3-7. doi: 10.1016/j.gore.2018.04.006
2. Liu S, Pan P, Han B, Wang J, Sun M, Sun Y. Extragastrintestinal Stromal Tumor Presenting as a Recurrent Vaginal Mass: Case Report. *Onco Targets Ther.* 2021;14:959-65. doi: 10.2147/OTT.S284101
3. Cheng M, Liu CH, Horng HC, Chen YJ, Lo PF, Lee WL, et al. Gastrointestinal stromal tumor presenting as a rectovaginal septal mass: A case report and review of literature. *Medicine (Baltimore).* 2019;98(17):e15398. doi: 10.1097/MD.00000000000015398
4. Hirota S. Differential diagnosis of gastrointestinal stromal tumor by histopathology and immunohistochemistry. *Transl Gastroenterol Hepatol.* 2018;3:27. doi: 10.21037/tgh.2018.04.01
5. Rodríguez-Abarca MA, Hernández-Grimaldo EG, De la Fuente-Villarreal D, Jacobo-Baca G, Quiroga-Garza A, Pinales-Razo R, et al. Gynecological influencing factors on the rectovaginal septum's morphology. *Int Urogynecol J.* 2021;32(6):1427-32. doi: 10.1007/s00192-020-04376-4