Malaysian Journal of Medicine and Health Sciences Vol. 4(2) June 2008: 55–70

An Updated Treatment of Complete Cleft Palate: a Retrospective Study

Ahmed Hussein Rahoma
Surgery Department, Faculty of Medicine, University of Technology Mara
Shah Alam 40450 Selangor, Malaysia

ABSTRACT

Objective: Complete cleft palate is still considered a complex problem. The proposed plan of management attempts to resolve the problem by adjusting the timing and steps of surgery. **Methods:** Forty-eight cases of unilateral and bilateral varieties were included in this study. Cases were operated by the author in King Khalid Civilian Hospital in Tabuk, Saudi Arabia and in University Malaya Medical Center, Malaysia, in the period from 1992 up to 2003. The study proposed to close the lip in the first week of life and palate by 7th to 10th month of age. **Results:** The results were satisfactory regarding closure, aesthetic appearance and speech improvement. Problems in the modified scheme are minor when compared with the classic scheme. **Conclusion:** Modifying the timing for treatment of complete cleft palate and lip allows early restoration of the normal anatomy of the mouth and face. This promotes normal growth of the facial skeleton and dentition, resulting in normal shape and good speech quality.

Keywords: Complete cleft palate, timing of treatment, steps of surgery

INTRODUCTION

Complete cleft palate is a complex problem. The results of management are mostly not satisfactory for both the surgeon and the patient. The treatment does not end by closing the cleft, but may extend beyond the age of 18 years or more (Photos No 1, 2 & 3). The incidence of speech problems, middle ear infections and palatal fistula encouraged us to take a new approach to treating this anomaly to achieve better results.

Incidence

Cleft lip and cleft palate are the most common congenital anomalies of the head and neck occurring in 1 in 700 live births. Among the Orientals, it is 1:500; in Caucasians, it is 1:2500; and in black Americans, it occurs the least, 0.4:1000. The highest incidence is in Asians while the lowest is in black Americans.[1,2]

Recent reviews suggest that clefts are due to multifactorial etiology involving many genes and environmental factors such as smoking, alcohol consupmtion, and anti-convulsion drugs.[3,4] Drugs during pregnancy, consanguinity, and exposure to radiation are commonly suggested environmental causes in the etiology. [1,2,3,7,8] Among the total number of clefts, 20% are an isolated cleft lip (18% unilateral, 2% bilateral), 50% are a

*Corresponding author: *ahmedhusseinr@yahoo.com* or *ahmedhussein@salam.uitm.edu.my*

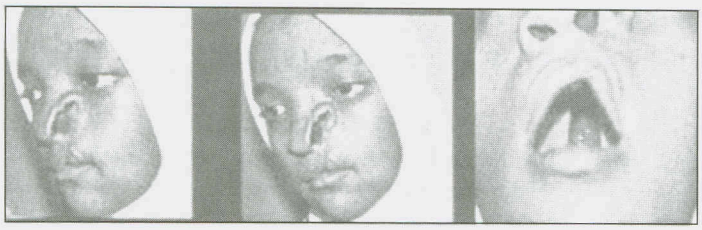

Photo 1: Malclosure of lip and neglected case in UMMC

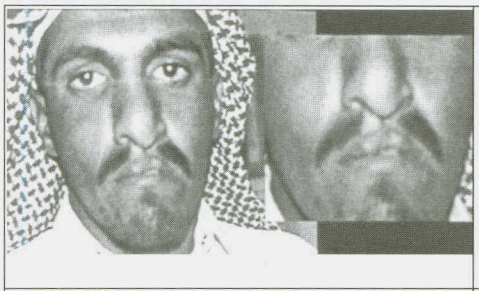

Photo 2: Example of bad surgery outcome in a Saudi Arabian adult male.

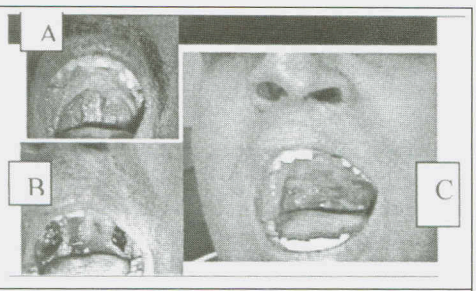

Photo 3: A 42-year-old-Malaysian with recurrent cleft after 3 previous trials; note also alveolar bone defect and mal-operated closed lip (A). He still has a strong nasal tone. After palate closure by author in Malaysia (B&C).

cleft lip and palate (38% unilateral, 12% bilateral), and 30% are cleft palate in isolation. The incidence of isolated cleft palate (without cleft lip) is 1 case in 2000 live births. Submucous cleft palate is more common with an incidence of 1 in 1200-2000 patients, depending on the study population. Bifid uvula occurs in 1 of 80 patients and often occurs in isolation, with no clefting of the palatal muscles.[1,9]

The incidence in Saudi Arabia was found (from statistics compiled by author) to be higher, up to 1:300 live births probably because of a high incidence of consanguity.[10] In Malaysia it is 1: 700[11] In a study carried out in 1990, Boo and Arshad[4] reported the incidence to be 1.24 per 1000 live births. The Chinese had the highest incidence of 1.9 per 1000 births, while the Malays had the lowest incidence of 0.98 per 1000 births and the most common type was reported to be the unilateral cleft of the hard and soft palates. [5]

From statistics compiled by the author in Tabuk region, North-west of Saudi Arabia, the incidence of cleft palate was found to be as high as 1:350 of lives births. For cleft lip or palate, it is 1: 250, which is considered higher than the international figure (1: 500-1000). [3,5]

METHODS

Study Sample

In this study, 48 cases of complete cleft palate were managed. This study was carried out in Saudi Arabia and Malaysia in the period from 1991 up to 2003 (Table 1). Some cases had a

Table 1. Nationality of patients

Saudi	Malaysian	Other
36	8	4

Table 2. Family history and associated conditions

Number of cases	48
Family	20
Brothers	14
Other clefts	16

Table 3. Complete cleft palate managed

Cases	No.	Percentage
Total cases	48	100%
Bilateral	18	37.5%
Unilateral	30	62.5%
Left sided	20	41.7%
Right sided	10	20.8%

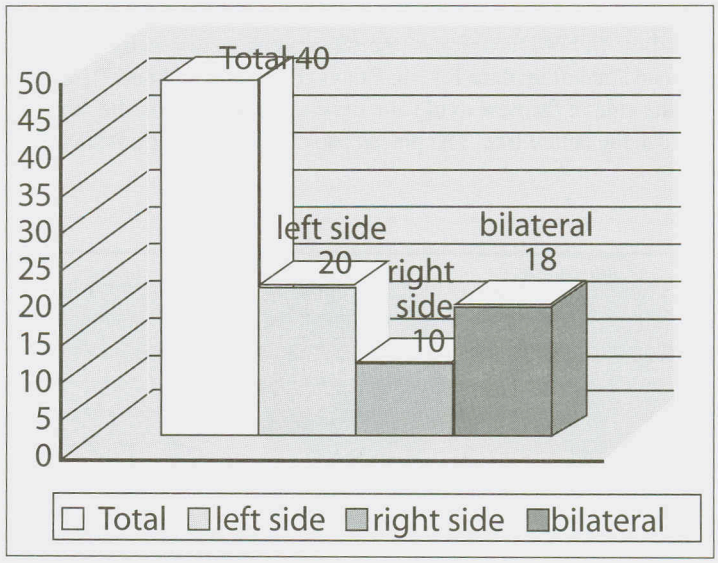

Figure 1. Operated cleft cases

family history of either brothers, sisters, or parents having the same problem. (Table 2)

The 48 patients were divided into two groups to facilitate comparing the new scheme and the old method as well as comparing two common popular techniques.

Grouping:

A. Classic Scheme

Cleft lip closure was carried out at three months of age. Some cases in this series were even seen after this age and we the authors describe them as neglected cases. The palate was closed before two years in this group (Group I = 23 cases) which included 8 cases using Veau-Wardil technique, and 15 cases treated by modified Von Langenbeck technique.[12,13,14]

B. Author's Modified Scheme

For Group II, the lip was closed in the first week of life while the palate was closed between 7 and 10 months of age. Twenty-five cases were treated in this way using the Modified Von Langenbeck technique.

Modification of Von Langenbeck Technique

This technique was modified by lateral palatal release incisions with wide dissection of the mucous membrane and muscle layers of palatal flaps and of the lateral walls of the oro-pharynx. Further, double opposing Z-plasties, one on the oral side and the other on the nasal side, were made in the soft palate to elongate the palate and uvula (Furlow's technique).[12,13,14] Backward stitch of the mucosa was done to help to narrow the velo-pharyngeral orifice. In both techniques, the other steps were greatly similar. Lateral gauze packs were placed and left in place for 3 to 5 days (Figures 2, 3, 4 and 7). Backward stitching of mucosa by the side of the new uvula and cress-cross stitches in the mucoperiosteal flaps helped to stabilise the suture line. The placed packs were kept for a sufficient period of time

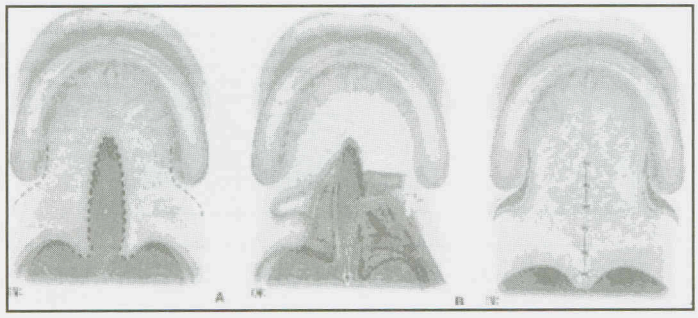

Figure 2. Illustration of Von Langenpeck – (After Pavy B, 1994)

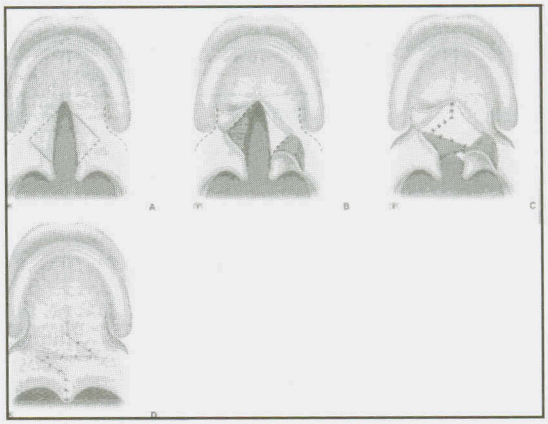

Figure 3. Illustration of Furlow's modification(Z- Plasty)

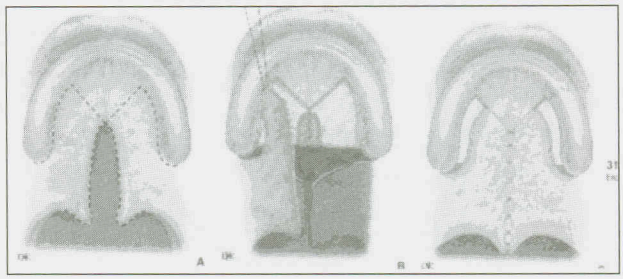

Figure 4. Illustration of Veau Wardil technique as in Pavy [10]

until good healing was achieved. Antibiotics were continued for 2 to 3 days. Post-operatively, the patient was given oral fluids and liquid diet for a week. Period of follow-up extended for the period of study, averaging two to eight years.

RESULTS

Six cases out of this series (48) had residual fistula. Out of the five cases in Group I (21.7%), three cases were treated using Veau-Wardil method (37.5 %) and two cases were treated using the Von-Langenbeck method (13.3 %); only one case in Group II (4%) was treated using the Von-Langenbeck method. In Group I fourteen of the 23 cases had speech problems (60.9%) while 6 of 25 cases in Group II (24%) had residual speech problems. Initiation of speech therapy brought the majority of these cases to a level of satisfaction as the other members in Group II, while in Group I, a few cases could be improved and three cases needed pharyngo-plasty to narrow the V-P orifice. The majority of cases achieved effective closure of the alveolar margins especially in Group II. Five cases in Group I (21.7%) and one case in Group II (4%) needed bone grafting for residual alveolar margin defects (Table 4 & Figure 5). It was left to the dental team to decide on the actual need for dental management.

Table 4. Complications related to each group

Complications	Technique		
	Group I		Group II
	VEAU-W (8 cases)	VON-L (15 cases)	VON-L (25 cases)
Bleeding	——	3	1
Stridors	——	2	1
Missed packs	1	1	——
Fistula	3	2	1
Speech problems	8	6	2
Dissatisfied parents	2	2	1

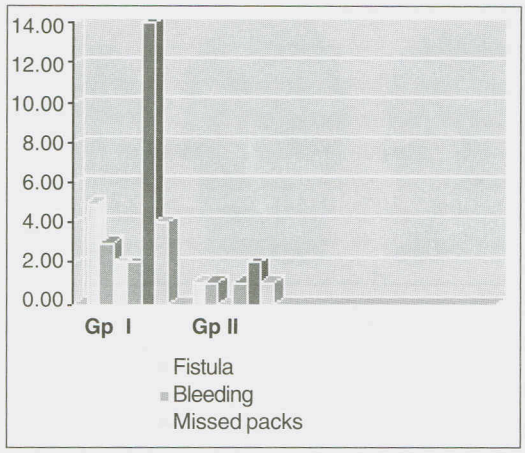

Figure 5. Complications in the two groups: speech problems = 16 cases; disatisfied parents = 4 cases; fistula = 6 cases; bleeding = 4 cases; stridors = 3 cases

DISCUSSION

Of the 48 cases, 18 (37.5%) had bilateral complete clefts, while 40 (62.5%) had unilateral complete clefts. Twenty cases had left clefts, 10 cases had right clefts, and 18 cases had bilateral clefts. The aim of management of complete cleft palate and lip problem is to close the lip and correct the shape as soon as possible to restore the anatomical features of the face. The main aim of early lip closure is to act as a cushion, exerting pressure on the alveolar margin to allow for good alignment of both parts of the alveolus and normal dentition. Follow up for further palate closure at a suitable timing is achieved to improve the speech. Follow up continued for sometime by the speech therapist as well as orthodontic and plastic surgeons. The combined work of the plastic surgeon, orthodontic surgeon, speech therapist, and a psychiatrist constitutes the task of the cleft palate team in both areas where the study was done.

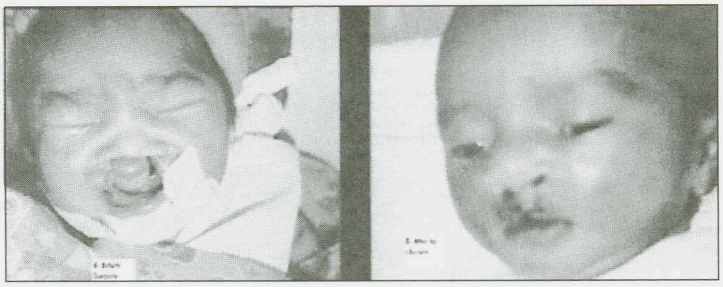

Case 1. Lip closure at one month (due to coagulation problems). UMMC

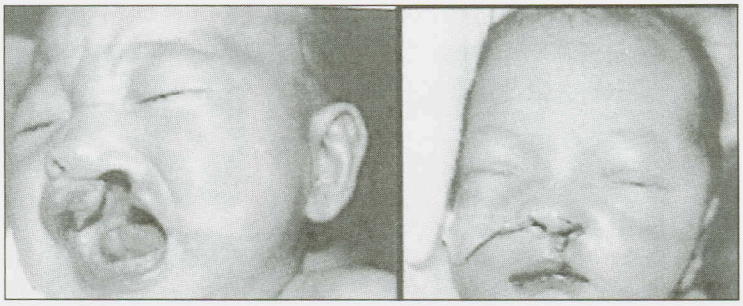

Case 2. Lip is closed in the 1st week of life. UMMC

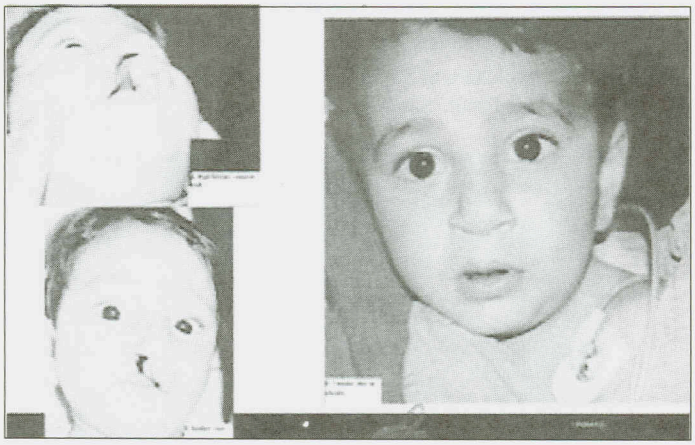

Case 3. Lip closed at 3 months and palate at 12 months in Saudi Arabia

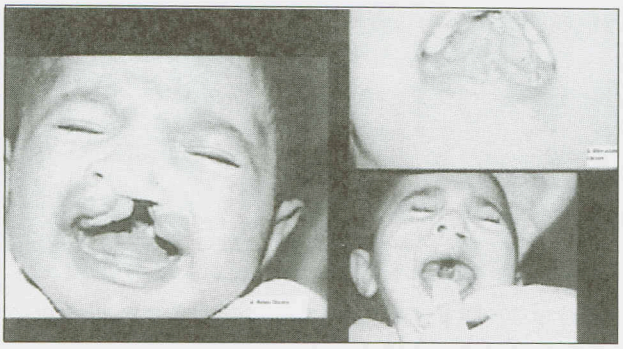

Case 4. Lip closed at 3 months, palate in later life. Saudi Arabia

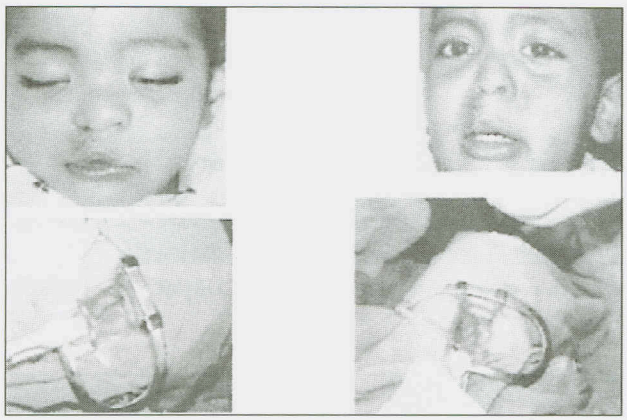

Case 5. Lip closure at 3 months and palate at 12 months- Palate closed well. Saudi Arabia

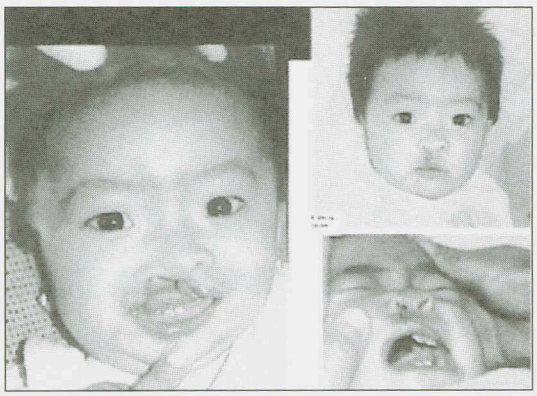

Case 6. Neglected case: Lip closure at 2 years of age – palate closed but residual fistula occurred. Saudi Arabia

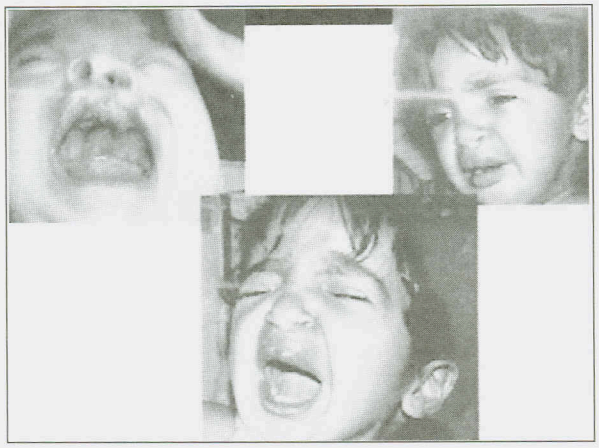

Case 7. Bilateral case after lip closure. Saudi Arabia

Case 8. Boy with lip and palate closed at 11 years of age. Saudi Arabia

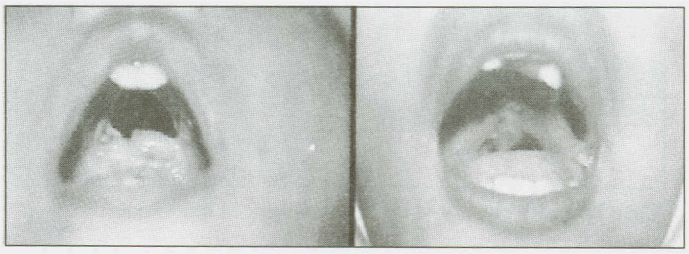

Case 9. Neglected case of palate after previous lip closure. No complications. UMMC

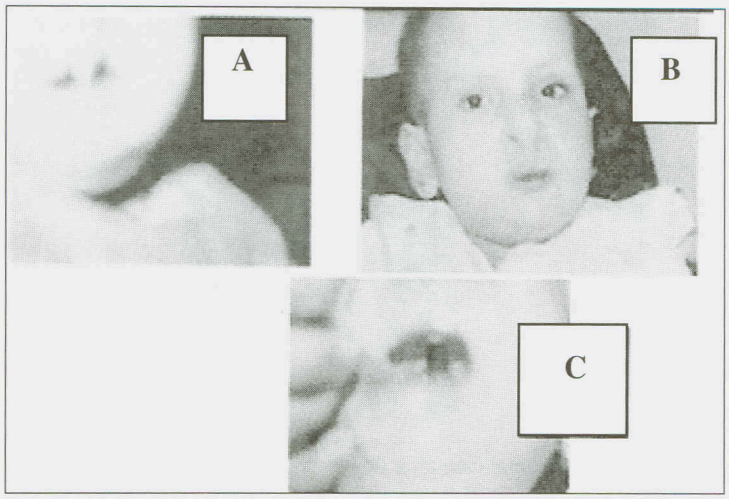

Case 10. Recurrent cleft lip after two trials at 1 year of age (A); after lip closure at one year (B); palate at time of closure which left a residual fistula (C). Saudi Arabia

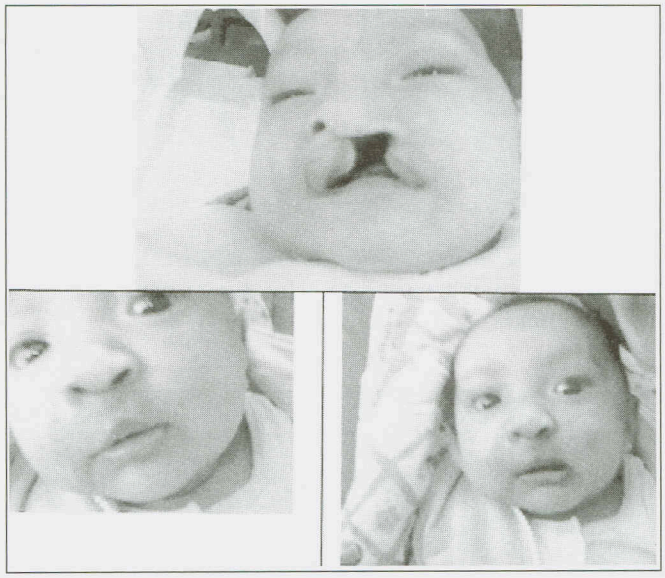

Case 11. Early closure of lip. Private work in Malaysia

Case 12. One-week-old baby at time of lip closure. Private work in Malaysia

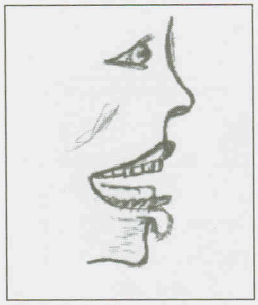

Figure 6. Ectropion of lower lip resulted in forward growth of teeth, due to lack of pressure by normal lip position.

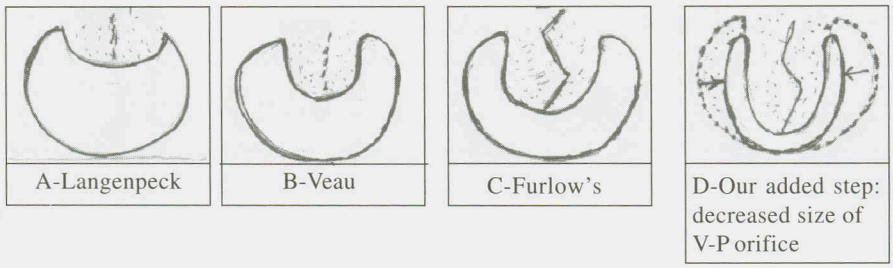

Figure 7. Uvula after closure using related technique showing the velopharyngeal orifice. Notice the size of V-P orifce with every technique

Jaques (1997)[15] and Rosenstein (1999)[16] recommended combined integrated cooperation between the plastic surgeon and the orthodontist from time of birth to adolescence for better or complete esthetics and function of all dentition.

Timing of Surgery

In this study, the author closed the lip by the first week of life. The main aim of early lip closure is to act as a cushion, exerting pressure on the alveolar margin to achieve good alignment of both parts of the alveolus. This will lead, by the seventh month of age, to approximate palatal shelves to the midline, and eventually change the complete variety to an incomplete type. This facilitates subsequent cleft closure. None of the patients who were operated in this scheme had any major residual complications as fistula, or failure of palate closure, or major speech problem. Speech improvement was achieved in the majority of cases treated by early lip closure as recorded by by the speech therapist during the follow up.

Posnick[17], Fukoda *et al.*[18], Lukash *et al.* [19] Mishima *et al.* [20] Serevans *et al.* [21] Brauman *et al.*[22] and Millard [23] had used pre-surgical casts or appliances to deal with the alveolar arch deformities until the surgery on the lip was achieved. They had good results, but the cost of the appliance is too expensive. It had been estimated then to be USD5000 per child.

The author observed a 40-year-old lady who presented with old burn and ectropion of lower lip showing forward projection of lower teeth that made the author think of early lip closure in cases of complete cleft varieties. In this study, the author used the lip as a natural appliance to help to approximate the palatal shelves, but it should be done as early as possible to achieve the required results. Pavy[12] in France started to close the lip in the first week of life. He is operating on more than 250 cases per year.

Heidbuchel *et al.*[24] studied the effects of early treatment on maxillary arch development in bilateral cleft palate. A study on dental casts between (0 and 4) years of age showed good results in relation to dental and speech outcomes.

Ysunza *et al.*[26] published a study on 41 patients with cleft palate who were operated at the age of 12 months, and 35 patients who were operated at the age of 6 months. He found that the speech outcome was significantly enhanced in the 6-month group, and no compensatory articulation disorders were seen. Both groups had the same degree of maxillary collapse which was less in cases operated early. This supports our early palate closure by the seventh month of age to achieve the best results for speech.

For bilateral clefts, it was found that delaying palatal surgery after the tenth month of age was better for achieving sufficient growth of the palatal shelves, and fusion of the primary palate and the alveolar arches. Complications in Group I were mainly due to delay in lip closure. This delay provides for greater stability of palatal shelves, arches, and alveolar margins in an abnormal anatomical area, which makes good closure difficult at a later stage.

Technique of Palate Closure

Two techniques were used, the Veau technique and Von Langenbeck technique. Najmi [27] used a full thickness skin graft; Malek as in Pavy[12] and Owman-Moll[25] closed the palate

in two stages. In our study, we used Von Langenpeck with Fowler's modification. We added the following improvements: wide dissection of lateral pharyngeal walls and maintaining the packs for few days in lateral slits created after moving the flaps. Hardens and Mazaheri[28] studied the effects of cleft palate on the growth of alveolar margins and also showed the effects of treatment. Takahashi *et al.*[29] started to do alveolar bone grafting for the residual alveolar notches. In our study, the need for alveolar bone grafting was reduced to a few cases with the modified plan, which allowed for good alignment of alveolar margins as it kept all teeth buds in place. Vacher *et al.*[30] studied the effects of treatment on the musculature of the soft palate and correlation to the outcome of treatment. This effect needs to be studied further. Speech therapy helped many patients in this study to improve their speech; improvements were more marked in patients treated by the modified scheme. Williams *et al.*[31] studied the velo-pharyngeal function after palatal surgery as well as the effects of speech therapy after treatment. In our study the speech therapist gave good comments on the speech outcome in patients treated early by the modified scheme.

CONCLUSION

For treating complete cleft palate, it is possible to start closing the lip early by the first week of life. This will help in achieving good alignment of the alveolus and normal dentition and decreases the chance of having major alveolar defects or notches. Also, it will help approximate the palatal shelves, changing the wide complete clefts to an incomplete type. Also, the palate closure can be achieved by the seventh to tenth months of age. Speech outcome in this plan is much better than in the classic scheme. Wide mucosal dissection and stitching back of mucosal walls of the pharynx, with double (Z) plasties have a beneficial effect on narrowing the pharyngeal orifice and results in improved quality of speech. We have contributed to cleft palate surgery by modifying the Von Langenbeck technique, and establishing a new timing for lip closure by the first week of life.

ACKNOWLEDGEMENTS

My deep thanks to Dato Professor Dr Khalid Yusoff, dean of the Faculty of Medicine UiTM, and to all the staff in Pediatric Department and Female Surgery Department in King Khalid Civilian Hospital in Tabuk, Saudi Arabia, and University Malaya Medical Centre. Thanks are also extended to Professor TM Ramanojam in UMMC for cooperation, understanding and help. Deep thanks also to Professor Yip Cheng Har and Professor Dr Azad Abdul Razek and the orthodontic department in UMMC and to Cleft Palate Association of Malaysian (CLAPAM). My deep thanks also to Ms Lim Lay Hoay and to all plastic surgery colleagues in Malaysia. Special thanks to Dr Siti Zaleha Mohd Saleh, Mr Abdullah Saleh and Mr Gerald Henry in Selayang Hospital.

REFERENCES

[1] Biavati MB, Rocha WG. Cleft Palate. eMedicine Specialties. Otolaryngology and Facial Plastic Surgery, Reconstructive Surgery, 14 November 2006.

[2] Kernahan DA, Stark RB. A new classification for cleft lip and cleft palate. Plast. Reconstr Surg 1958; 22: 435.

[3] Denk Michael J. Pediatric surgery for the primary care pediatrician, Part II. Pediatric Clinics of North America 1998; 45(6):1479-1506.

[4] Boo NY, Arshad AR. A study of cleft lip and palate in neonates born in a large Malaysian maternity hospital over a 2 –year period. Sing Med J;1990; 31: 59-62.

[5] Ghani SHA, Hassan R, Hassan S *et al.* Cleft Lip and Palate Center: The University Hospital Experience: Annals Dent. Univ. Malaya, 1996: 3: 27-37.

[6] Stark RB. Pathogenesis of harelip and cleft palate. Plast Reconstr Surg 1954; 13:22.

[7] Decker GAG, Du Plessis DJ. Developmental anomalies of the face and branchial arches. In : Synopsis of Surgical Anatomy, 1980.

[8] His W. Die Entwickelung der menschlichen und thierischer Physiognoen. Arch. Anat. Physiol. Anat, part 384, 1892 Beobachtungen zur Geschichte der Nasen und Guamenbildung im meuschlichen Embryo. Abhandl. Math. Phys. Classe Kgl. Sachs. Gesellsch. Wissensch 1901; 27: 347

[9] El Rakhawy MT. The palate. In: Illustrative anatomy: head and neck, 1978.

[10] Wyszynski DF, Maestri N, Mc Intosh I *et al.* Evidence of an association between markers on chromosome 19q and non-syndromic cleft lip with or without cleft palate in two groups of multiplex families. Human Genetics 1997; 99(1): 22-6.

[11] Zainul Ahmad Rajion, Zilfalil Alwi. Genetics of cleft lip and palate: a review. Malaysian Journal of Medical Sciences 2007;14: 14-9

[12] Pavy B: Traitement secondaire des fentes labiales et palatines. In: Banzet P, Servant JM (eds). Chirurgie plastique, reconstructive et esthetique, Paris: Flammarion Medicine-Sciences1994; 253-267.

[13] Lindsay WK. Surgical repair of cleft palate. Clin Plast Surg 1975; 2: 309

[14] Von Langenbeck B. Uranoplastic by detaching the mucous periosteal lining of the hard palate. Arch Klin Chir 1861; 2: 205.

[15] Jaques B, Herzog G, Muller A, Hohlfeld J, Pasche P. Indications for combined orthodontic and surgical (orthognathic) treatments of dentofacial deformities in cleft lip and palate patients and their impact on velopharyngeal function. Folia Phoiatrica et Logopedica 1997; 49 (3-4): 181-93.

[16] Rosenstein SW. Two unilateral complete cleft lip and palate orthodontic cases treated from birth to adolescence. American Journal of Orthodontics & Dento-facial Orthopedics 1999; 115(1) : 61-71

[17] Posnick JC. Orthognathic surgery for the cleft lip and palate patients. Seminars in Orthodontics 1996; 2(3): 205-2014.

[18] Fudoka M, Takashi T, Yamagushi T, Kochi S. Placement of endosteal implants combined with chin bone onlay graft for dental reconstruction in patients with grafted alveolar clefts. International Journal of Oral and Maxillofacial Surgery. 199? 827(6): 440-444

[19] Lukash FN, Schwartz M, Gruer S, Tuminelli F. Dynamic cleft maxillary orthopedics and periosteoplsty: benefit or detriment? Annals of Plastic Surgery 1998; 40 (4): 321-326; Discussion 326-327.

[20] Mishima K, Sugahara T, Mori Y, Minami K, Sakuda M. Effects of presurgical orthopedic treatment in infants with complete bilateral cleft lip and palate. Cleft Palate-Craniofacial Journal 1998; 35(3): 227-32.

[21] Severens JL, Prahl C, Kuijpers-Jagtman AM, Prahl- Anderson B. Short-term cost effectiveness analysis of presurgical orthopedic treatment in children with complete unilateral cleft lip and palate. Cleft Palate-Craniofacial Journal 1998; 35(3): 222-6

[22] Braumann B, Keilig L, Bourauel C *et al*. Three dimensional analysis of cleft palate casts. Anatomischer Anzeiger 1999; 181(1): 95-8.

[23] Millard DR, Latham R, Huifen X, Spiro S, Morovic C. Cleft lip and palate treated by presurgical orthopedics, gingivo-periosteoplasty, and lip adhesion (POPLA) compared with previous lip adhesion method ; a preliminary study of serial dental casts. Plastic & Reconstructive Surgery 1999; 103(6): 1630-1644.

[24] Heidbuchel KL, Kuijpers-Jagtman AM, Van't Hof MA, Kramer GJ, Prahl-Anderson B. Effects of early treatment on maxillary arch development in bilateral cleft palate . A study on dental casts between 0 and 4 years of age. Journal of Cranio-Maxillo- Facial Surgery1998; 26(3): 140-147.

[25] Owman-Moll P, Katsaros C, Friede H. Development of the residual cleft in the size of cleft palate after velar repair in a 2-stage palatal repair regimen. Journal of Orofacial Orthopedics. 1998; 59(5): 286-300,

[26] Ysunza A, Pamplona MC, Mendoza M, Garcia-Velasco M, Aguilar MP, Guerrero ME. Speech outcom and maxillary growth in patients with unilateral complete cleft lip/ palate operated at 6 months versus 12 months of age. Plastic and Reconstructive Surgery, 1998; 102(3): 675-679.

[27] Nadjmi N, Jackson IT. Full thickness skin graft in secondary repair of bilateral cleft lip and palate; a case report. International Journal of Oral & Maxillofacial Surgery. 1999; 28(3): 176-8

[28] Hardins RL, Mazaheri M. Gowth and spatial changes in the arch form in bilateral cleft lip and palate patients. Plastic and Reconstructive Surgery 1972; 1:50-59

[29] Takahashi T, Fukuda M, Yamaguchi T, and Kochi S. Use of endosseous implants for dental reconstruction of patients with grafted alveolar clefts. Journal of Oral & Maxillofacial Surgery 1997; 55(6): 576-583; discussion 584

[30] Vacher C, Pavy B, Ascheman J. Musculature of the soft palate : clinico-anatomic correlations and therapeutic implications in the treatment of cleft palate. Cleft Palate Craniofacial Journal 1997; 34(3): 189-194.

[31] Williams WN, Seagle MBS *et al.* A methodology report of a randomized prospective clinical trial to assess the velopharyngeal function for speech following palatal surgery. Controlled Clinical Trials 1998; 19(3): 297-312.