

CASE REPORT

Primary Focal Segmental Glomerulosclerosis and Minimal Change Disease as one Spectrum of Disease

Then Ru Fah¹, Tan Yi Jun², Christopher Thiam Seong Lim³

¹ Department of Nephrology, Serdang Hospital, 43000 Kajang, Selangor, Malaysia

² Department of Medicine, Serdang Hospital, 43000 Kajang, Selangor, Malaysia

³ Unit of Nephrology, Department of Medicine, Faculty of Medicine and Health Sciences, Universiti Putra Malaysia, 43400 Serdang, Selangor, Malaysia

ABSTRACT

Minimal Change Disease (MCD) and Focal Segmental Glomerulosclerosis (FSGS) are common causes of nephrotic syndrome. These two conditions are similar in their presentations but differentiated via their histopathological features and responsiveness to corticosteroids. There are ongoing debates whether MCD and FSGS are at the same spectrum of disease rather than separate entities. FSGS has been postulated to be the severe end of the spectrum of MCD. We have reported a case that has primary FSGS after years of poorly controlled MCD, which supports both conditions are the same spectrum of disease.

Keywords: Minimal change disease, Focal segmental glomerulosclerosis, Progression, Spectrum, Corticosteroid

Corresponding Author:

Christopher Lim

Tel: +603 8947 2568

E-mail: drchrislim@gmail.com

INTRODUCTION

Minimal change disease (MCD) is the most common cause for idiopathic nephrotic syndrome. MCD is characterized by heavy proteinuria that leads to intravascular volume depletion, hypoalbuminemia and edema. The presentation of MCD can be seen mostly in young children and some in adults. In paediatric population, MCD accounts for almost 90% of cases in idiopathic nephrotic syndrome (1). In adults, MCD only accounts for 10 – 25% of cases. Other causes of nephrotic syndrome in adults that needs to be considered are FSGS or membranous nephropathy. MCD and focal segmental glomerulosclerosis (FSGS) are both examples of glomerulopathy that primarily affect the podocyte. Until recently, there has not been much report that show the progression of MCD into FSGS over the years. We report here a rare occurrence of FSGS in a patient who is known to have MCD.

CASE REPORT

Our patient is a 19-years-old teenager was diagnosed with MCD at the age of 9. He was started on prednisolone until the age of 15-year-old where he subsequently defaulted

treatment. At the age of 16-year-old, he developed another episode of relapsed of nephrotic syndrome. Renal biopsy done confirmed the diagnosis of MCD. He was reinitiated on corticosteroids. Unfortunately, he defaulted all follow-ups and represented to us with relapsed of nephrotic-nephritic syndrome. His initial blood result shows: urea 20.7 mmol/L, creatinine 522 µmol/L, albumin 7 g/L, urine analysis protein 4+ and blood 1+ and urine protein creatinine ratio approximate to 24 gram of proteinuria per day. His baseline creatinine one year ago was 75 µmol/L. Renal biopsy was repeated and showed moderately advanced focal segmental glomerulosclerosis with 38% of global sclerosis evident. Immunofluorescence staining was negative for IgG, IgA, IgM, C3, C1q, fibrinogen, Kappa and Lambda. (Figure 1 and 2). Patient was restarted on diuretic and corticosteroids. Angiotensin converting enzyme inhibitor was subsequently added when renal function started to show improvement. He responded well with improvement in proteinuria and renal profile. His latest blood tests revealed serum creatinine 153 µmol/L, albumin 49 g/L and urine protein creatinine approximate to 0.9 gram of proteinuria per day.

DISCUSSION

MCD which is a major cause of idiopathic nephrotic syndrome presented with proteinuria, edema, intravascular depletion, and hypoalbuminemia with no glomerular lesions by light microscopy (or only minimal mesangial prominence), no staining on

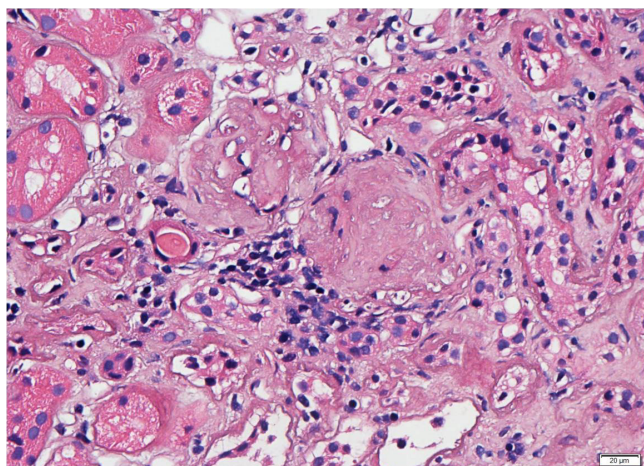


Figure 1 : Glomeruli show global sclerosis and segmental sclerosis (H and E)

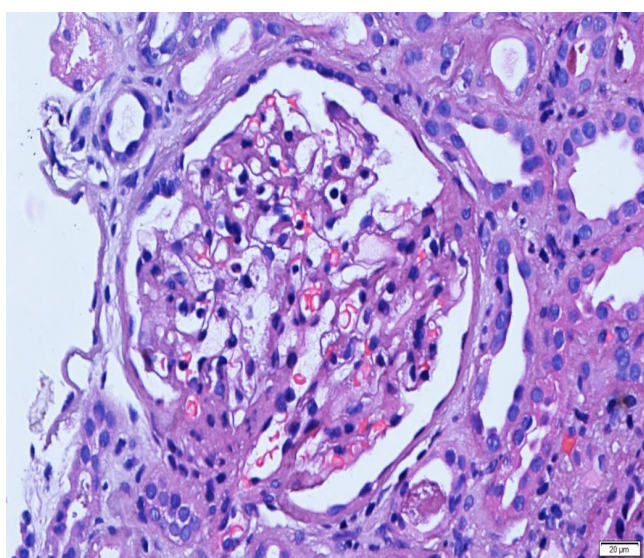


Figure 2: Mild mesangial proliferation with focal synaechaeformation (H and E)

immunofluorescence microscopy (or low intensity staining for C3 and IgM) and foot process effacement but no electro-dense deposits on electron microscopy. MCD in children usually responds to corticosteroid. Therefore, corticosteroid treatment has always been started in MCD without renal biopsy unless steroid resistance or alternative diagnosis is being considered. The underlying cause of MCD is associated with systemic T cell dysfunction resulting in production of a glomerular permeability factor (1). The factors will directly affect glomerular capillary wall causing marked proteinuria and fusion of foot process. There has always been a debate that MCD and FSGS falls within the same spectrum of disease or a separate pathogenetic entities. MCD will have full nephrotic syndrome, evidence of complete effacement of podocyte on electron microscopy, good response to immunosuppressants and

rarely progress to chronic kidney disease.

On the other hand, FSGS is a disease entity defined by findings of sclerotic and non-sclerotic glomerular lesion on renal biopsy. FSGS alone can be classified as primary, secondary or genetic forms. Clinical presentation of primary FSGS or idiopathic FSGS is similar with MCD where patient presented with nephrotic syndrome. It has been hypothesized that the initial podocyte injury is the critical step that lead to potential progression to FSGS. The extent of this injury, the vulnerability of the podocytes, the presence of additional factors (such as diabetes and hypertension) and the response to therapy will determine whether FSGS lesions will develop or not.

Secondary FSGS will have non-nephrotic range proteinuria with certain degree of renal impairment and less clinical severity as compared with primary FSGS. This condition can be seen due to adaptive response to glomerular hypertrophy or hyperfiltration towards condition that causes reduction of nephron mass, scar from a healing inflammatory lesions or toxicity from drugs and viral infection. Genetic mutations in genes that codes for proteins expressed in podocytes and slit diaphragm can cause FSGS as well. Presentation of genetic cause of FSGS varies in terms of degree of proteinuria and nephrotic syndrome. Diagnosis of underlying cause and differentiating type of FSGS needs to be established to ensure the appropriate treatment. Postulated mechanism that leads to progression from MCD to FSGS when the patient has poorly controlled nephrotic syndrome include the persistent tubulointerstitial fibrosis and inflammation inflicted by the on-going proteinuria. Proteinuria can potentially contribute to the tubulointerstitial fibrosis by activation of the inflammatory and/or profibrotic pathways in tubular cells and injuring podocytes at the same setting (2).

Data from our Malaysia registry of renal biopsy (MRRB) (over a period of 7 years with 8,298 biopsies) showed that prevalence of MCD and FSGS from renal biopsies are 32% and 29% respectively for primary glomerulonephritis. The incidence of FSGS is peak at those patients aged 15-25 years old and there after the incidence slowly decreased with advancing age. In the registry, common presentation of FSGS include nephrotic syndrome (57.3%), asymptomatic urinary abnormalities (24.6%) and mixed nephritic-nephrotic at 5.7%. Contrary to common belief, it is not a benign disease as 15% of the patients were noted to have progressed to ESRD over a period of 72 months follow up. Up to a third of the patients were note to have suffered from hypertension at the time of diagnosis of FSGS (3).

Primary FSGS or idiopathic FSGS is highly associated with MCD. Our case shows similar findings of Tejani et al. where 15 patients out of 33 patients who has frequent

relapses from MCD, have progressed to FSGS (4).

Corticosteroid therapy as a mainstay of treatment for FSGS already has numerous reports that support the efficacy of it. A retrospective analysis shows 63% of patients attained remission after initiating corticosteroid. Another study reported 58% of the patients with biopsy-proven FSGS responded well to corticosteroid. Overall remission rates of 57 – 66% have been reported with complete remission rates of 32% - 47% and partial remission rates of 19 – 29% (5). However, there are other advanced therapies for FSGS that can be considered if a patient is not responding to corticosteroid therapy such as cyclophosphamide, calcineurin inhibitor, mycophenolate mofetil, mizoribine or biologic treatment.

CONCLUSION

We have shown that FSGS can arise from a poorly controlled MCD, thus supporting the notion that MCD and FSGS are the same spectrum of disease with FSGS being the severe form of the spectrum. In view of the

poor prognosis of FSGS, attention must be given to MCD patients to ensure the optimal renal outcome.

REFERENCES

1. Cho MH, Hong EH, Lee TH, Ko CW. Pathophysiology of minimal change nephrotic syndrome and focal segmental glomerulosclerosis. *Nephrology (Carlton)*.2007;12:S11-4
2. Fogo AB. Causes and pathogenesis of focal segmental glomerulosclerosis. *Nature reviews Nephrology*. 2015;11(2):76-87.
3. Rosnah Y, Wan Jazilah W I. 5th Report of The Malaysian Registry of Renal Biopsy 2012.June 2014.National Registry Malaysia.
4. Amir Tejani. Morphological Transition in Minimal Change Nephrotic Syndrome. *Nephron*.1985;39:157-159
5. Hee Han K, Heon Kim S. Recent Advances in Treatments of Primary Focal Segmental Glomerulosclerosis in Children. *Biomed Res Int*. 2016;2016:3053706