

CASE REPORT

An Incidental Finding of Internal Jugular Vein Ectasia on Cervical Spine Magnetic Resonance Imaging

Noor Khairiah A. Karim^{1,2}, Noor Hasyima Mat Zain²

¹ Regenerative Medicine Cluster, Advanced Medical and Dental Institute, Universiti Sains Malaysia, Bertam, 13200 Kepala Batas, Pulau Pinang, Malaysia

² Imaging Unit, Advanced Medical and Dental Institute, Universiti Sains Malaysia, Bertam, 13200 Kepala Batas, Pulau Pinang, Malaysia

ABSTRACT

Ectasia or abnormal dilatation of a vessel may affect any vein within the body including the neck region. Internal jugular vein (IJV) ectasia commonly presents as a painless, soft swelling on the neck which appears to be prominent with increased intrapleural pressure such as during Valsalva manoeuvre. To the best of our knowledge, the occurrence of venous ectasia is infrequent with limited number of reports on this anomaly available. However with the advancement of technology especially in imaging modalities, there is improvement in detecting this condition. We describe here an incidental finding of focal IJV ectasia in an elderly lady following a cervical spine magnetic resonance imaging (MRI) for bilateral hand numbness, and discuss the management of this rare presentation.

Keywords: Internal jugular vein ectasia, Cervical spine MRI, Valsalva manoeuvre, Doppler USG

Corresponding Author:

Noor Khairiah A. Karim, MBBS, MRad
Email: drkhairiah@usm.my
Tel: +604-5622516

INTRODUCTION

Internal jugular vein (IJV) ectasia is an underreported anomaly of the vein whereby it is aneurysmally dilated and presents as a painless, soft swelling on the neck. The swelling may not be obvious and is more visible with increased intrapleural pressure such as when performing Valsalva manoeuvre and even during sneezing, coughing, crying or straining (1,2). It tends to be unilateral, and normally affecting the right side as compared to the left. The diagnosis can be confirmed by non-invasive imaging modalities such as ultrasonography (USG) with additional Doppler examination during rest and while performing Valsalva manoeuvre. The management is conservative for asymptomatic patients or in those with no disturbing symptoms and for those with complications, surgery should be considered.

CASE REPORT

Mdm. PP is a 74 year-old lady who presented with bilateral hand numbness which was not relieved with

physiotherapy. There was no history of neck pain. On physical examination, there was numbness over the median and ulnar nerve areas, extending to base of palmar regions. There was also associated wasting of thenar muscles. Hence, magnetic resonance imaging (MRI) of cervical spine was performed, demonstrating degenerative intervertebral disc disease with incidental finding of fusiform aneurysmal dilatation of the right IJV extending along the level of C3 to T1 vertebrae, measuring 2.9 x 1.7 cm in maximum diameter suggestive of phlebectasia (Fig. 1). No obvious mass effect of the dilated right IJV to the exiting spinal nerve roots at this level. The larynx and hypopharynx were normal with no abnormal soft tissue mass seen. She was not aware of any neck swelling even on sneezing, coughing, crying, straining or speaking loud. She did not complain of any changes in her voice, having dysphagia or breathing difficulties. There was no previous history of surgery or trauma to the neck and chest region. The examination of other systems was normal. Clinically at rest, there was no obvious swelling seen on the neck region. However, on performing Valsalva manoeuvre, a right-sided neck swelling was seen. The swelling was visible just lateral to sternocleidomastoid muscle extending till supraclavicular fossa. The swelling was soft and painless, and compressible on palpation. The overlying skin was unremarkable. There was no obvious pulsation seen over the swelling. There was no associated lymphadenopathy. The lesion had regular borders and

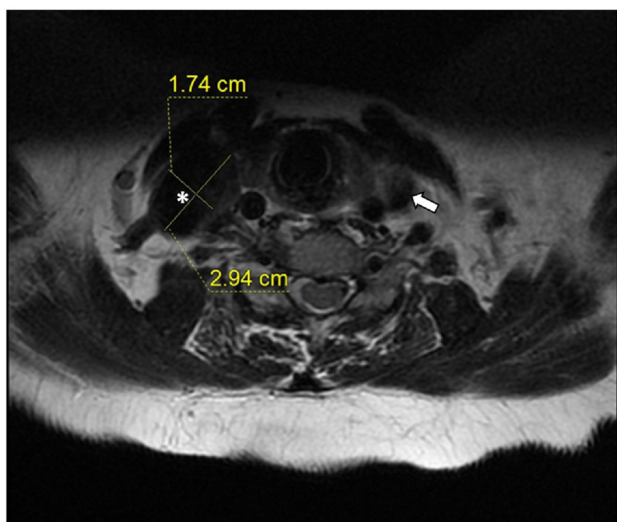


Figure 1: Axial MRI, showing dilated right IJV (white asterisk) measuring 2.9 x 1.7 cm in maximum diameter as compared to normal left IJV (white arrow) on T2-weighted image

did not elevate with deglutination.

The diagnosis was confirmed by Doppler USG. The USG revealed focal dilatation of the right IJV measuring 2.1 x 1.2 cm in maximum diameter, which further dilated to 3.1 x 1.6 cm during Valsalva manoeuvre (Fig. 2). The left IJV at the same level at rest was 0.8 x 0.7 cm in diameter with no significant changes in size during Valsalva manoeuvre. There was no evidence of thrombosis. Color Doppler demonstrated turbulent flow within the right IJV. These findings were consistent with right IJV ectasia.

DISCUSSION

Ectasia is the medical term used to describe aneurysmally dilated vessel without tortuosity within the body including the vein at the neck region (3). The neck veins that may be affected are anterior, internal and external jugular veins (4). In 1929, the first case of IJV ectasia was reported and the anomaly was further described by Gerwig in 1952 (3). This condition is seen usually during childhood affecting the right side and because of its benign appearance and character, it may possibly be underdiagnosed. Our patient was 74 years old at the time of diagnosis, perhaps one of the oldest ever documented in the literature.

The aetiology of this condition is unknown however few causes of IJV ectasia have been proposed which include congenital origin, anomalous reduplication of IJV, irradiation of superior mediastinum and trauma. Previous histopathology examinations of resected specimen have revealed connective tissue hypertrophy with thickening of the focal intima and loss of elastic layer. The right IJV is usually larger than the left in normal persons. This has been attributed to the more frequent tendency of the straight sinus to empty to the right transverse sinus rather than to the left transverse sinus. Therefore, proportionately more blood is delivered from the cranial venous system to the right jugular vein. An increased intrapleural or intrathoracic pressure may directly be transferred to the right innominate vein due to its contact with right apical pleura and subsequently to right IJV, hence the reason for phlebectasia to be commonly seen on the right side. In addition, the higher placement of the right IJV valves and almost absence of valves in the

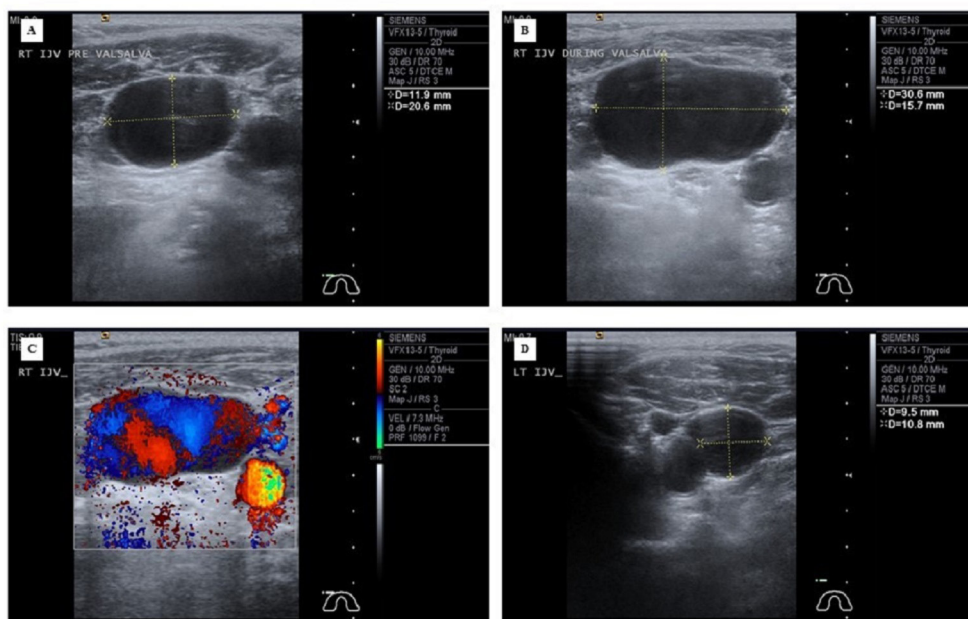


Figure 2: Ultrasonography shows the right IJV at rest (A) and during the Valsalva manoeuvre (B). Color Doppler demonstrated turbulent flow within the right IJV (C). The left IJV at the same level at rest was normal in diameter (D) with no significant changes in size during Valsalva manoeuvre.

right innominate vein may contribute to the occurrence of this condition. If pronounced, this tendency would produce relative dilatation of the right IJV throughout the whole length. However in this patient, this abnormality was rather to be a true aneurysm and unlikely to be a normal variation although lacking histopathologic evidence, because of the focal ectasia seen on USG and the focal palpable fullness which increased in response to Valsalva manoeuvre and with any other similar action. While those with this condition are often asymptomatic, they can also present with discomfort during deglutination, hoarseness upon phonation, a feeling of a cervical foreign body, constriction, and the sensation of choking. An enlarging painless swelling on the neck is normally seen during straining and when patient is relaxed, it completely disappears (1,4). The differential diagnosis for this presentation include a laryngocoele, tumour or cyst arising from superior mediastinum, laryngeal diverticulum and cavernous haemangioma.

Accurate diagnosis can be obtained by using non-invasive imaging modalities such as computed tomography and MRI. However, the ideal imaging method to diagnose this anomaly would be by Doppler USG while the patient is resting, during and after performing Valsalva manoeuvre. It has the capability to differentiate the venous enlargement, define the degree of extension and relationship with adjacent neck structures, and to evaluate for thrombus formation and external compression. Color Doppler flow studies can demonstrate turbulent vascular flow within the affected segment during Valsalva manoeuvre, due to proliferation of connective tissue and disordered arrangement of elastic fibres in the vessel wall.

As this condition appears to be self-limiting and benign, conservative follow-up is advised and surgery is not recommended unless in those with disturbing symptoms (5). Long-term follow-up includes serial USG to evaluate for lesion growth or thrombosis. However, because of the rarity of this condition, no clear guidelines for the frequency and intervals of follow-up have been established. Surgery is appropriate in symptomatic phlebectasia or in cases with complications such as thrombus formation, phlebitis, cosmetic deformity,

and rupture, and even for cosmetic reasons. There are various surgical options available which include ligation of feeding vessels followed by dilated segment resection, and using graft at the affected segment. Surgical complications include craniofacial swelling, thrombosis, and intracranial hypertension. As the patient in our case was asymptomatic, she was recommended for follow-up with USG.

CONCLUSION

This case brings to light the possibility that jugular vein ectasia is often overlooked by family or physicians. Although rare and only few have been reported till date, this entity has a relatively characteristic clinical scenario and an easy method of diagnosis. Further assessment can be done using non-invasive measures such as USG with colour Doppler. The management is conservative for patients with no or minimal disturbing symptoms and for those with complications, surgery should be considered.

ACKNOWLEDGEMENT

The authors gratefully thank to all those indirectly involved in preparing this case report.

REFERENCES

1. Vinod Kumar G, Ranganatha Reddy B, Bhat SM, Vuppala R. An intriguing case of ectasia of external jugular vein presenting as intermittent neck mass. *Indian J Otolaryngol Head Neck Surg.* 2016; 68(3): 367-369.
2. Aydoğan F, Taştan E, Aydın E, et al. Bilateral internal jugular vein phlebectasia. *Ear Nose Throat J.* 2011; 90 (3): E1-3.
3. Gerwig WH. Internal jugular phlebectasia. *Ann Surg.* 1952; 135: 130-133.
4. Abdulla SA, Aldabagh MH. Congenital phlebectasia of the internal jugular vein. *Dohuk Med J.* 2008; 2: 155-159.
5. Bowdler DA, Singh SD. Internal jugular phlebectasia. *Int J Pediatr Otorhinolaryngol.* 1986; 12: 165-171.