

CASE REPORT

Fatal Non-traumatic Fat Embolism

Norhafizah Mohtarrudin¹, Iskasymar Itam @ Ismail²

¹ Department of Pathology, Faculty of Medicine and Health Sciences, Universiti Putra Malaysia, 43400 UPM Serdang, Selangor, Malaysia

² Department of Medicine, Faculty of Medicine and Health Sciences, Universiti Putra Malaysia, 43400 UPM Serdang, Selangor, Malaysia

ABSTRACT

Non-traumatic fat embolism (NTFE) is infrequently encountered in the clinical setting. The incidence of clinically detected fat embolism is less than 1%. It is diagnosed based on the evidence of fat emboli occluding the vessel lumen in a patient with no prior history of trauma. We report a case of NTFE in a lady who developed breathlessness and collapsed following home vaginal delivery. Post-mortem examination revealed extensive fat emboli in the pulmonary vessels. We elucidate the clinical challenges in diagnosing fat embolism (FE) in a patient without history of trauma.

Keywords: Non-traumatic, Fat embolism, Fat emboli

Corresponding Author:

Norhafizah Mohtarrudin, MPath
Email: norhafizahm@upm.edu.my
Tel: +603-9769 2608

INTRODUCTION

Fat embolism (FE) occurs when fat macro globules enter blood circulation. It may result in fat embolism syndrome (FES) leading to multisystem dysfunction with an overall mortality of 5–15% (1). The exact number of cases presented with FES are unknown. Many cases presented with mild symptoms might have been missed and under diagnosed. There are two types of FE i.e. traumatic FE and NTFE. NTFE is comparatively rare than FE. Nevertheless, it shows similar manifestations with traumatic FE. NTFE following vaginal delivery is even rarer. We report a case of NTFE in a patient who developed respiratory distress following vaginal delivery.

CASE REPORT

A 32-year-old lady was brought to the Emergency Department at 0720 and triaged to Red Zone. She was brought in with no signs of life. She was declared dead at 0755 am (thus, her death was categorized as Brought in Dead). The deceased was a G3P2 at 38 weeks and 5 days. She was apparently healthy with no significant past medical or surgical history. Antenatal history was uneventful, and the pregnancy was booked.

The problem started when the deceased complained of headache and developed labour pain at 0430. She

had a vaginal delivery of a cephalic presentation at 0530. The blood loss was claimed to be minimal. Soon after delivery, she had shortness of breath and was unconscious. She was brought to the nearby hospital. Cardiopulmonary resuscitation (CPR) was attempted but cardiac rhythm was asystole throughout. She was declared dead according to the Adult Advanced Life Support algorithm. On examination, her uterus was well contracted. Blood investigations revealed: haemoglobin: 11.6 g/d, white cell counts: $30.2 \times 10^9/L$ and platelet: 38,000 /mCL (agglutinated). Venous blood gas was at pH 6.6 and HCO_3^- 3. The baby had normal birth weight with no gross congenital abnormalities or evidence of trauma.

Post-mortem was performed to confirm the possible cause of death and to rule out foul play. On examination, there was no evidence of petechial rash, injury, cervical tear, or any other significant pathological changes. Musculoskeletal system examination revealed no evidence of closed fracture of the long bones. The uterus was well contracted and empty with no evidence of retained products of conception. Both lungs were congested and weighed 640 grams and 480 grams respectively. There was no evidence of pulmonary saddle thromboembolism in the pulmonary trunk or in any of its branches.

Microscopically, both lungs were congested. The pulmonary vascular lumens were obstructed by fat emboli and other haematopoietic series/bone marrow. (Fig. 1) There was no foetal squames, lanugo hair, vernix, and mucin obstructing the vessels, thus the possibility

of amniotic fluid embolism was excluded. None of the vessels show evidence of thrombosis, hence the differential diagnosis of pulmonary thromboembolism was excepted. Sections from the brain did not show evidence of petechial haemorrhage to suggest fat embolism. Examination of the heart, kidneys, liver, gastrointestinal tract, bladder and other organs were within normal limits. No other significant pathological changes were identified.

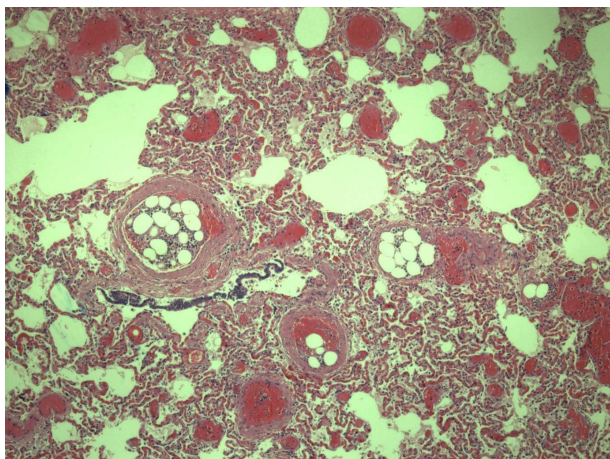


Fig. 1a : Fat embolism in the pulmonary vasculatures. Section from the lung shows presence of fat and haematopoietic series/bone marrow occluding the vessels. (Haematoxylin and Eosin stain, Original Magnification x40)

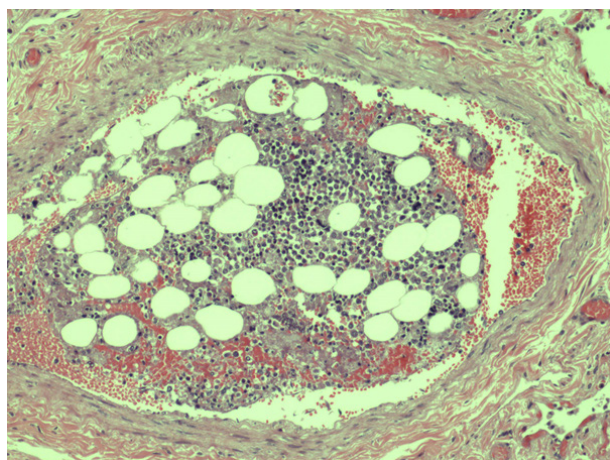


Fig. 1b : Bone marrow/ fat emboli occluding the blood vessel (Haematoxylin and Eosin stain, Original Magnification x100)

DISCUSSION

Post-mortem examination of the patient showed normal pregnancy changes with no evidence of dermal changes or trauma. The only significant finding was the presence of widespread fat embolism in the pulmonary vasculatures. Comparatively, pulmonary thromboembolism and amniotic fluid embolism are more common than FE during pregnancy and puerperal period. Nonetheless massive FE has been reported in pregnant women who were on chronic corticosteroid therapy and sickle cell anaemia (2). Based on the history, apparently there was no significant predisposing factors for FE in this patient. (Table I)

Table I: Causes of fat embolism

Traumatic fat embolism	Non-traumatic fat embolism.
<ul style="list-style-type: none"> • Long bone, pelvic and other marrow-containing bones fractures • Orthopaedic procedures (intramedullary nailing, pelvic and knee arthroplasty) • Massive soft tissue injuries • Severe burns • Liposuction • Bone marrow biopsy, harvesting and transplant • Median sternotomy • Cardiopulmonary bypass/resuscitation 	<ul style="list-style-type: none"> • Pancreatitis • Diabetes mellitus • Osteomyelitis and panniculitis • Bone tumour lyses • Corticosteroid therapy • Lymphography • Sickle cell haemoglobinopathies • Alcoholic (fatty) liver disease • Lipid fusion/ fat emulsion infusion • Cyclosporine • Epilepsy

The exact pathogenesis of FE is not well defined. The most acceptable mechanisms are described in biochemical and mechanical theories. NTFE may best be explained by biochemical theory. According to the biochemical theory, tissue lipases break down bone marrow fat and catecholamine mobilises fatty acids and forms fat micro emboli that cause toxic injury to the endothelium. This leads to platelets activation and granulocytes recruitment, thus releasing free radicals, protease and eicosanoids that eventually occlude the vasculature. In mechanical theory, fracture bone or soft tissue trauma tears the tissues surrounding the vessels. This allows bone marrow from the fractured bone or adipose tissue from the injured soft tissues entering the vascular lumen and obstructing the blood vessels.

The other possible cause of FE is traumatic CPR. CPR is a routine procedure performed in a cardiac arrest patient. It comprises manual chest compression accompanied with artificial ventilation aiming at restoring blood circulation and breathing. Excessive chest compression may lead to fractures of rib and sternum and cause mechanical entry of fat globules into the vasculature. These have been reported in 20-30% of autopsy studies (3). In our patient, although CPR was attempted, nonetheless there was no evidence of antemortem rib fractures, hence traumatic cause could be ruled out. Other studies have reported high incidence of pulmonary FE i.e. in more than 80% of patients who received CPR in both non-traumatic patients and traumatic patients (2). Nonetheless, in many cases, the source of fat emboli and its effect on the physiology of these patients remain unclear and require further investigation.

FE is usually asymptomatic. In symptomatic cases, the symptoms usually manifested 24 to 72 hours after the injury occurred. Seldom, the symptoms occur by 12

hours or two weeks later. The classical triad of FES are respiratory insufficiency, neurological impairment, and petechial rash. The incidence of FE who presented with symptoms have been reported in 1% to 29% of the patients (1). The only significant clinical signs in our patient were rapidly progressive dyspnoea and loss of consciousness with no evidence of petechial rash.

Respiratory manifestations vary from mild symptoms as manifested with dyspnoea and/or tachypnoea to severe respiratory distress, characterized by symptoms and signs of ARDS. Subsequently the patient may progress into pulmonary hypertension, cor pulmonale, congestive heart failure or even death if the conditions are not treated adequately and promptly.

Neurological manifestations (confusion, stupor or coma) usually occur following respiratory dysfunction. Obstruction of the brain vasculature may lead to headache. Petechial rash, a pathognomonic of FES usually present on the oral mucosa, conjunctiva and skin folds of the upper part of the body especially over the neck and axilla. It occurs due to dermal capillary occlusion and increased capillary fragility. In 20–50% of cases, the rash disappears within hours (4).

Nonetheless, there were reported cases that presented with skin rash, neurological symptoms, fever, increased heartbeat and low blood pressure without any respiratory symptoms. Clinically, Gurd, Schonfeld and Lindeque criteria have been used widely as a guideline to diagnose FE (5). Continuous pulse oximetry might be able in identifying FE in high-risk patients.

There are no specific diagnostic tests to confirm FE. Patients with FE may develop thrombocytopenia, anaemia, hypofibrinogenemia, or urinary fat globules. These findings are nonspecific and cannot be used as a confirmatory test. The role of imaging in diagnosis of FE is still debatable. Hence diagnosis is mainly on clinical criteria; often made by exclusion or by histopathological examination.

There was still lack of literature on perinatal fat emboli. In our case; FE might have been the result of increased level of neurotransmitter i.e. catecholamines and mobilisation of fat globules into maternal circulation during parturition. The predisposing factors for this case remain obscure. Nonetheless, sudden maternal respiratory decompensation should trigger suspicion for fat embolization besides amniotic fluid embolization.

CONCLUSION

NTFE is uncommon yet fatal. In many cases, autopsy is warranted to confirm the presence of fat embolization in the vasculature. Complete medical history, autopsy examination and high index of suspicion is imperative to determine the accurate diagnosis.

ACKNOWLEDGEMENT

We would like to thank the editors and reviewers in charge of MJMHS for giving us the opportunity to share our case and we hope it will be beneficial to the readers. We also would like to acknowledge Universiti Putra Malaysia and the hospital involved.

REFERENCES

1. Shaikh N. Emergency management of fat embolism syndrome. *J Emerg Trauma Shock*. 2009;2(1):29-33.
2. Ferah Karayel, Nadir Arican, Gamze Kavas et al. Maternal Death Due to Non-Traumatic Fat Embolism. *J Forensic Sci*. 2005; 50 (5).
3. Evert Austin Eriksson, Daniela C. Pellegrini, Wayne E. Vanderkolk, et al. Incidence of Pulmonary Fat Embolism at Autopsy: An Undiagnosed Epidemic. *J Trauma*. 2011; 71:312–315.
4. Morales-Vidal SG. Neurologic Complications of Fat Embolism Syndrome. *Curr Neurol Neurosci Rep*. 2019;19(3):14.
5. Miller, RD et al. *Miller's Anaesthesia*. 7th ed. Churchill Livingstone; 2009.