ORIGINAL ARTICLE

Apium Graveolens Linn Affects Fibroblast and Collagen Density on the Incision Wound Healing

Tan Hengky[1], Indah Saraswati[2], Hermawan Istiadi[2], Vega Karlowee[2], Muflihatul Muniroh[2], Endang Mahati[2]

[1] Biomedical Masters Student – General Surgery Resident, FK UNDIP/ RSUP Dr. Kariadi, 50244 Semarang, Indonesia
[2] Department of Physiology, Faculty of Medicine, Diponegoro University, Tembalang, 50275 Semarang, Indonesia

ABSTRACT

Introduction: Incision wounds occupy the third position (23.2%) of all types of injuries. Wound healing treatment which using chemicals has had a negative impact in the process of wound healing, and therefore the utilization of natural ingredients that contain anti-inflammatory and antioxidant increasingly being used by the public. The purpose of this study was to prove the effect of *Apium graveolens Linn* to incision wound healing particularly on fibroblast and collagen density. **Methods:** This research is a randomized post test with control group design which used 20 rats and divided randomly into four groups, which were given treatment for 7 days. Control group received cream without *Apium graveolens Linn*, positive control group received antibiotic gentamicin cream 0.1%, while the intervention group received various doses (50 and 70%) of *Apium graveolens Linn* topically. Fibroblast and collagen density areas were assessed microscopically by 2 anatomical pathologists. Data were analyzed and processed using the Oneway ANOVA - Post Hoc Bonferroni test. **Results:** There were significant differences in the fibroblast density area between the Apium graveolens Linn extract 50% group (p=0.022), and *Apium graveolens Linn* extract 70% (p=0.019%) with the control group, respectively. There was a significant difference in collagen density between *Apium graveolens Linn* 50% extract group (p=0.023) and *Apium graveolens Linn* extract 70% (p=0,000) with the control group, respectively. **Conclusion:** Apium graveolens Linn extract can accelerate the healing process of incision wounds by increasing fibroblast and collagen density areas.

Keywords: *Apium graveolens Linn*, Incision wound healing, Fibroblast, Collagen

Corresponding Author:
Tan Hengky, MD
Email: tan_hengky91@yahoo.co.id
Tel: +62-8886449715

INTRODUCTION

Humans can not be separated from physical activities such as cooking, cutting , and other activities. Activities can cause problems if there is negligence during activities. One problem caused by negligence is wound. Wounds can be defined as damage or disruption to normal anatomical structures and functions (1). This can vary from superficial damage or can be deeper, which can extend to subcutaneous tissue or other structures (1). Based on the time of wound healing, wound can be divided into acute and chronic wounds (1). Acute wounds occur when wound healing occurs between 5-10 days, while chronic wounds are wounds that fail to pass the wound healing phase and there are no signs of recovery (1). Wounds based on the cause of the wound base are divided into open and closed wounds. Incision wounds are a type of wound that can be categorized as an open wound (2). Based on data from riskesdas in 2013, incision wounds came in third place (23.2%) after bruises and abrasions (70.9%) and sprained wounds (27.5%) (3).

After the injury occurs, body will respond with wound healing (1). Wound healing is part of a complex physiological process (4,5). This stage consists of a series of reactions and interactions between cells with various kinds of mediators, where the process starts from hemostasis, fibroblasts, inflammation, angiogenesis with the end result of increasing collagen fibers (4,5).This process is divided into several phases, the first phase is an inflammatory phase that aims to remove dead tissue and prevent the process of infection (5). The next phase is the proliferation phase, the proliferation phase is where the formation of granulation tissue is accompanied by a large number of new blood vessel tissues, as well as macrophages in the supporting tissue. The second

phase runs from the 8th to the 21st day after the wound, where this phase is the phase of epithelialization and the remodeling phase is the last phase that occurs (4,5).

Fibroblasts are a major component of wound healing process and appear first on the 3rd day, where these cells react to the increase in cytokines produced by macrophages and lymphocytes (1,4-5). Increased fibroblasts in the wound area will produce collagen as the main element in the wound healing process (1). Collagen is a triple chain glycoprotein, which is the main element of the extracellular matrix that gives strength to scar tissue (1).

Collagen is produced to connect tissues and is useful for rebuilding tissues (5). Collagen plays an important role in the formation of scar tissue in the healing process, where collagen synthesis in the proliferation phase can be optimal (1,5). High collagen density in the proliferation phase is a sign of the rapid healing process of wounds which can ultimately reduce the potential for scar tissue to form (6,7).

Recently the use of topycal antibiotics as a prophylaxis and treatment of wound infection are common. Gentamycin has been proven to increase the clinical efficacy and shorten the wound healing duration, however the risk of resistance development is also high (8). Therefore, it is necessary to look for other alternatives for wound healing that are safe, easily available and effective.

Herbal plants as an alternative treatment for wounds can be seen from a study conducted by the Riskesdas in 2013, of which a total of 294,969 households, found that 26.4% did self-medication without medical assistance, and from that number 15.7% of them use traditional medicine (3). In Indonesia, there are many medicinal plants used by the community for wound healing, medicinal plants such as guava leaves, binahong, god leaves, tempuyung, mangkokan leaves, pineapple fruit, garlic, shallots, celery leaves (*Apium graveolens Linn*), and other.

Based on previous studies on pharmacological activity of *Apium graveolens Linn* leaves, it has caffeic acid, coumaric acid, pherulic acid, apigenin, luteolin, tannins, saponins, and kaempferol compound, which has a powerful anti-oxidant and anti-inflammatory effect and thought to be able to accelerate the process of wound healing and accelerate the epithelialization process through its ability to reduce the duration of the inflammatory process, and produce collagen III factor which is responsible for wound closure in the initial phase of wound healing (9-11).

Research of Apium graveolens Linn extract on its anti-inflammatory effect has been carried outt, therefore, based on the description above, the researchers intend to conduct research on the administration of Apium graveolens Linn extract to cure Sprague Dawley rat incisions by investigating the fibroblast and collagen density areas.

MATERIALS AND METHODS

Animals and treatments

This experimental study was designed on 20 Sprague Dawley rats with ages 2-3 months and weight ± 140-200 grams which were divided into 4 groups will be acclimatized in the laboratory for one week in individual cages. All rats will be given a 5 cm long incision wound with a depth of 2-3 mm on the right back. During acclimatization and treatment, rats will be treated at room temperature 28-32oC, and get food and water ad libitum. Before treatment, rats were given anesthesia with a Ketamine-Xylazine mixture (Ketamine dose 80mg/kgBB; dose of Xylazine 10mg/kgBB intraperitoneally. Rats were divided into 4 groups randomly with 5 rats per group. Every day, rats will be given topical cream without Apium graveolens Linn extract, gentamicin 0.1%, 50% Apium graveolens Linn extract, and 70% Apium graveolens Linn extract, respectively.

Histopathological examination

On the 7th day of the study, all rats will be terminated and wound tissue will be taken and processed to be examined for microscopic preparations by hematoxylin-eosin (HE) and masson trichrome staining. Fibroblast and collagen density areas were blindly assessed by 2 anatomical pathologists using microscope. In the fibroblast density area, we multiply the length and width of the area with the greatest fibroblast density and used a 40 x magnification and for collagen density variable, we add up all the percentages of collagen density and divide by 5 fields used 5 fields with a 100 x magnification.

Statistical Analysis

Data were analyzed and processed fibroblast density area and collagen density using the Oneway ANOVA - Post Hoc Bonferroni test.

RESULTS

Sample characteristics

Tabulation of the sample weight of 20 individuals, each were taken on the 7th day of acclimatization where the day was also the first day of the treatment process. We can concluded that the average body weight of mice is overall homogeneous and has been in accordance with the inclusion criteria of the study. But among these groups, the 50% Apium graveolens Linn extract group had the highest average body weight, which was equal to 160.60 grams.

Fibroblast density area

Table I shows the results of mean and deviations standart from fibroblast density area against the control group,

the Gentamicin cream group and the treatment group. Calculation of the fibroblast density area is the average result of measuring the area of fibroblast density in the cross section of the wound area. Fibroblast density area measured from the most active part which is free of debris, both in length and width in a square micrometer unit. The table shows that on the 7th day there has been a wound healing process that is in the proliferation phase and is characterized by an area of fibroblast density, and also shows that the mean area of fibroblast density in the extract group Apium graveolens Linn 70% had the lowest area of fibroblast density compared to the other groups.

Table I : Characteristics of the area of fibroblast density (in units of μm²)

Group	N	Mean	Deviation standart
Control	5	5,641	0,491
Gentamicin cream	5	4,538	0,817
Extract Apium graveolens Linn 50%	5	4,040	0,649
Extract Apium graveolens Linn 70%	5	4,008	0,934

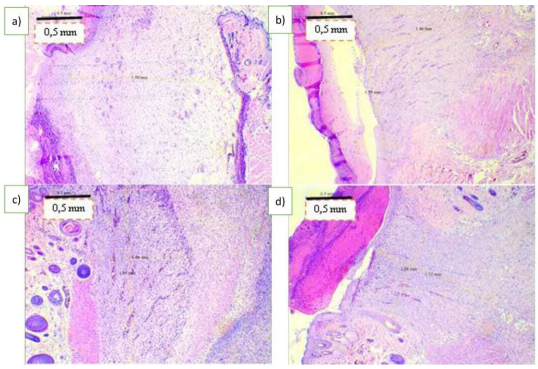

Fig. 1 : Histopathological description of fibroblast density area with hematoxylin-eosin staining.
a. Control, b. Gentamicin cream, c. extract Apium graveolens Linn 50%, d. extract *Apium graveolens Linn* 70% with 40 x magnification.

Microscopic observations of the area of fibroblast density were carried out using 100 x magnification and can be seen in Fig. 1. Median of fibroblast density area from extract Apium graveolens Linn 70% group that lower than other groups and the normality test and data homogeneity of each group were carried out using the Shapiro-Wilk test because the number of samples was less than 50 samples. Data exploration for each variable is normally distributed and homogeneous in all groups (p>0.005). From Oneway ANOVA test, we found p value=0.01, because p<0.05, it can be concluded that there is a significant difference between the average area of fibroblast density between groups. Furthermore, the Post Hoc Bonferroni test was used to determine differences between groups. From the results of the Post Hoc Bonferroni test, there were significant differences between the groups given Apium graveolens Linn extract 50% and the control group p=0.022 and between groups of Apium graveolens Linn extract 70% with the control group p=0.019.

Collagen Density

Collagen density observed from 5 field of view, taken from cross sections of each group can be seen in Fig. 2. The collagen density is presented in the form of percentage of the field of view and then measured in magnitude. Table II shows the results of the mean and deviations standart of collagen density in all groups. Table II shows the average of the collagen density in the extract Apium graveolens Linn is 70% higher than the other groups.

Table II : Characteristics of total collagen density (%)

Group	N	Mean	Deviation standart
Control	5	51,7	6,620
Gentamicin cream	5	56,6	1,387
Extract Apium graveolens Linn 50%	5	59,6	1,474
Extract Apium graveolens Linn 70%	5	66,0	2,549

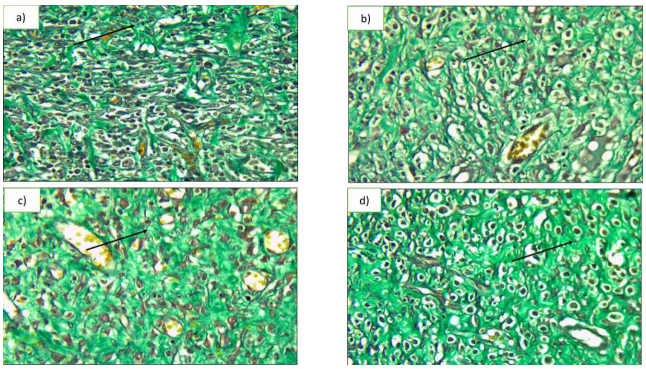

Fig. 2 : Histopathological features of collagen density with trichrome staining (green).
a. Control, b. Gentamicin cream, c. extract Apium graveolens Linn 50%, d. extract Apium graveolens Linn 70% with 100 x magnification, 10 field of view.

The normality test and data homogenity of each group were carried out using the Shapiro-Wilk test because the number of samples was less than 50. Exploration for each variable in each group can be seen in the Table IV. From One Way ANOVA test p<0.05, it can be concluded that there are significant differences in the collagen density in all groups. Furthermore, the Post Hoc Bonferroni test was used to determine differences between groups. From Post Hoc Bonferroni test, there was a significant difference between Apium graveolens Linn extract 50% with control p=0.023, and between Apium graveolens Linn extract 70% with controls p=0,000 and between Apium graveolens Linn 70% with gentamicin cream p=0.006.

DISCUSSION

This study aims to prove the effect of Apium graveolens Linn to incision wound. The discussion of the results of the study was carried out sequentially starting from rat body weight, area of fibroblast density and collagen density.

After the treatment for 7 days, the results of the average rat weight between groups on the 7th day of acclimatization were in accordance with the inclusion criteria, this needs to be conveyed because the ideal body weight is one of the conditions for the healing process occur normally (12).

The average area of the lowest fibroblast density was in the treatment group using Apium graveolens Linn cream 70% compared to the control group and other treatment groups. Then followed by the treatment group by using 50% Apium graveolens Linn cream. This is in line with the theory which states that the wound healing process starts from the inflammatory phase which begins with the presence of a lesion which will be followed by the secretion of cytokines in the form of PDGF, TGF Beta, EGF, and insulin like growth factor (1). PDGF and TGF Beta are pro-inflammatory cytokines that stimulate the migration of fibroblasts to the injured area (1). Then the fibroblasts will turn into miofibroblasts which have contractile ability so that the wound edges will be attracted and then close to the edge of the wound will stick (13). This caused the area of fibroblast density in the treatment group to have a lower area compared to the control group.

After a statistical test of the area of fibroblast density, there was a significant difference in the treatment group by using 50% Apium graveolens Linn extract cream and the treatment group using Apium graveolens Linn extract cream 70% of the control group in the wound healing process. This is in accordance with the theory which states that Apium graveolens Linn contains various active ingredients, one of which is flavonoids namely apigenin and apiin which have the ability as anti-inflammatory and antioxidant agents (14-16). This potential for anti-inflammatory and antioxidant causes in the treatment group found a smaller area of fibroblast density than the control group. In line with the research conducted by Mencherini in 2007 and Sapri Yss in 2017, who stated that Apium graveolens Linn has anti-inflammatory potential which in the results of its research turned out Apium graveolens Linn can reduce edema of the ears and feet of mice given kroton oil (9,15).

There was no statistically significant difference between the treatment group and the gentamicin cream group indicating that the treatment group using Apium graveolens Linn extract cream could replace the use of gentamicin cream in the treatment of wounds. The absence of statistically significant differences between Apium graveolens Linn extract 50% and 70% illustrates that the results are comparable to the wound healing process in terms of fibroblast density area.

Collagen is a substrate produced by active fibroblasts and shows an advanced phase of healing. Collagen density in the treatment group using Apium graveolens Linn 70% cream, had the highest number among the other groups, then followed by the 50% Apium graveolens Linn extract cream. Based on the theory, Apium graveolens Linn extract contains Apigenin and Apiin which is one of the flavonoids that can trigger TGF, where TGF is one of the factors that stimulates the growth of fibroblasts to produce collagen. In theory the wound will enter the inflammatory phase along with the appearance of the wound, and will soon be followed by the emergence of fibroblasts on the third day of the inflammatory phase which will be followed by the synthesis of collagen, the presence of antioxidant and anti-inflammatory potential in Apium graveolens Linn can trigger fibroblasts to produce collagen the basic ingredients of the wound healing process (17).

After a statistical test of collagen density, it was found that there was a significant difference in the treatment group by using 50% Apium graveolens Linn extract cream and the treatment group by using 70% Apium graveolens Linn cream from control group at level of collagen density. This is in accordance with the theory which states that antioxidants will trigger fibroblasts in producing collagen (14-16, 18-19).

There was no statistically significant difference between the treatment group and the gentamicin cream indicating that the treatment group using Apium graveolens Linn extract cream could replace the use of gentamicin cream in the treatment of wounds. The absence of statistically significant differences in collagen density between Apium graveolens Linn extract cream 50% and cream Apium graveolens Linn extract 70% illustrates that both these treatments give results comparable to the wound healing process in terms of the density of collagen.

In this study, it also has a weakness in the form of extracts and creams given to experimental animals not from pure isolation so that compounds that play an important role as agents that accelerate wound healing cannot be determined. In addition, the way mice treat wounds is also different from humans so that the bias in the healing process of wounds due to the use of experimental animals in the form of rat cannot be avoided.

CONCLUSION

Apium graveolens Linn was effective in reducing the area of fibroblast density and was effective in increasing collagen density in Sprague Dawley rat incision wounds. To improve the concept of thought on this study, further research is needed to know the active compounds of

Apium graveolens Linn which has the greatest role on the process of wound healing. So that, this study can be used as a basic for human clinical testing of the herbal plant products in the form of plant Apium graveolens Linn as a therapeutic or phitofarmaka.

ACKNOWLEDGEMENT

This study was supported by research grant from Faculty of Medicine Diponegoro University. We also would express our gratitude for all of the staff of Pathology Anatomy department UNS who provided the histological samples for this experiment.

REFERENCES

1. Velnar T, Bailey T, Smrkolj V. The wound healing process: an overview of the cellular and molecular mechanisms. J Int Med Res. 2009;37(5):1528-42.
2. Nastity HGM, Mulya HR. Uji Efek Penyembuhan Luka Sayat Ekstrak Etanol Daun Kecombrang (Etlingera Elatior) Dalam Bentuk Sediaan Gel Terhadap Kelinci (Oryctolagus Cuniculus). JF FIK UINAM. 2015; 3:54-8.
3. Kementrian Kesehatan RI. Riset Kesehatan Dasar. Jakarta: Menkes; 2013. p40-47
4. Sjamsuhidajat JD. Buku Ajar Ilmu Bedah. 4 ed. Jakarta: EGC; 2017. P404-410.
5. Prasetyono TOH. General concept of wound healing, revisited. Med J Indones. 2009; 18:208-16.
6. Meilang XJJC. Extracellular Matrix Reorganization During Wound Healing and Its Impact on Abnormal Scarring. Adv Wound Care. 2015;4(3):119-36.
7. Aravindan RKGH, David L. Role of collagen in wound management. Wounds UK. 2011;7(2)54-63.
8. Wang P, Long Z, Yu Z, Liu P, Wei D, Fang Q, et al. The efficacy of topical gentamycin application on prophylaxis and treatment of wound infection: A systematic review and meta-analysis. Int. J Clin Pract. 2019; 73(5):e13334.
9. Sapri ESS, Ariska Y. Uji Aktivitas Antiinflamasi Fraksi Air Ekstrak Daun Seledri (Apium graveolens L.) Pada Mencit Jantan. JIIS. 2017; 1:60-7.
10. Kooti W, Ali AS, Asadi SM, Ghadery H, Ashtary LD. A review on medicinal plant of Apium graveolens. pharmacogn Rev. 2015;1(1):48-59.
11. Al-Asmari A, Athar T, Kadasah S. An Updated Phytopharmacological Review on Medicinal Plant of Arab Region: Apium graveolens Linn Pharmacogen.rev.2017; 11:13-8
12. Barchitta, M, Maugeri, A, Favara, G, Magnano, R, Evola, G, Agodi, A, et al. Nutrition and Wound Healing: An Overview Focusing on the Beneficial Effect of Curcumin. Int. J. Mol. Sci. 2019. 20(1): 1-14.
13. Amita, K, Balqis, U, Dahlia, C.I. Histophatological Finding of The Vulnus Incisivum Healing in Mice (Mus musculus) using Anredera cordifolia Leaf Extract. Jimvet. 2017. 1(3): 584-91.
14. Aslam MS, Ahmad MS, Riaz H, Raza S. A, Hussain S, Qureshi OS, et al. Role of Flavonoids as Wound Healing Agent In Phytochemical.2018; 6(1):95-102.
15. Wojcik KA, Skoda M, Koczurkiewicz P, Sanak M, Czyz J, Michalik M. Apigenin inhibits TGF-1 induced fibroblast-tomyofibroblast transition in human lung fibroblast populations. Pharmacol Rep. 2013; 65(1): 164-172.
16. Mencherini T, Cau A. Bianco G, Loggja RD, Aquino RP, Autore G. An extract of Apium graveolens var. dulce leaves: structure of the major constituent, apiin, and its anti-inflammatory properties. 2007; 59(1): 891-97.
17. Zhu, Y, Cankova, Z, Iwanaszko, M, Lichtor, S, Mrksich, M, Ameer, G. A. Potent Laminin-Inspired Antioxidant Regenerative Dressing Accelerates Wound Healing in Diabetes. PNAS. 2018. 115(26): 6816-21.
18. Akbik, D, Ghadiri, M, Chrzanowski, W, Rohanizadeh, R. Curcumin as a Wound Healing Agent. J. Life Sci. 2014. 1(1): 1-7.
19. Brown, M. S, Ashley, B, Koh, A. Wearable Technology for Chronic Wound Monitoring: Current Dressing, Advancements, and Future Prospects. Front Bioeng Biotechnol. 2018. 1(6): 1-21.