SYSTEMATIC REVIEW

Effects of Human Amniotic Membrane (HAM) on Rectovaginal Fistula Healing: A Systematic Review and Meta-analysis of Animal Studies

Riska Wahyuningtyas[1], Eighty Mardiyan Kurniawati[2]

[1] Department of Obstetrics and Gynecology, Faculty of Medicine, Universitas Airlangga, Soetomo Hospital, Surabaya, 60115, Indonesia
[2] Urogynecology Reconstruction Division, Department of Obstetrics and Gynecology, Faculty of Medicine, Universitas Airlangga, Soetomo Hospital, Surabaya,60115, Indonesia

ABSTRACT

Introduction: Rectovaginal fistula causes distressing symptoms of the patients since the passage of stool and gas make them embarrassing as well as there is still high recurrence rate after repair surgery. Animal model study is important in the process of new surgery invention. Human Amniotic Membrane (HAM) is a bio-material with evidence in wound healing process. Our aim was to evaluate effects of HAM on rectovaginal fistula healing in the past animal studies systematically. **Methods:** We searched related articles in Pubmed, Google Scholar, and Science Open database from 2010 to October 2020. We found 12 articles then a total of 2 studies were included and reviewed systematically. Risk of bias study was assessed using SYRCLE tool. Data of healing score were analyzed using Revman 5.3 software. **Results:** We identified 2 studies reporting effect of HAM on rectovaginal fistula healing in animal studies, one of them were using 8 dogs and other were using 8 rabbits. We evaluated 2 groups, HAM and fistulectomy (experimental group) and fistulectomy only group (control group). These studies evaluated both grossly and microscopically after 4-6 weeks observation. In gross examination, there is no abscess formation, infection or pussy discharge in both groups. There is significant different in healing score (Pathologist review) between two groups (experimental and control group) (mean difference 1.94[95%CI (1.23-2.66)], $p < 0.00001$, with higher healing score in experimental group).
Conclusion: HAM is a promising bio-material in wound healing of rectovaginal fistula of animal.

Keywords: Human amniotic membrane, Rectovaginal fistula, Healing score, Fistulectomy, Animal studies

Corresponding Author:
Riska Wahyuningtyas, MD
Email: riska.wahyuningtyas23@gmail.com
Tel: +6281289839447

INTRODUCTION

Rectovagina fistula is multi etiology disease clinically characterized by any connection between rectum to vagina. The most common causes are due to injury, surgical procedure or any underlying disease. Laceration of third and fourth degree perineum after vaginal delivery, surgery in which damages the vaginal and rectal, malignancy and also Crohn's disease, are the most common causes (1). Patients with rectovaginal fistula will suffer for fecal incontinence, anal irritation, passage of gas and fecal involuntary from vagina, recurrent infection of vagina and dyspareunia (1,2). Thus, emotional, social and physical suffering due to this rectovagina fistula symptoms will cause any psychological effects even depression of patients (3).

Surgery is needed in 99% patients with rectovaginal fistula (4). There are many considerations in choosing surgical approaches. They were chosen based on etiology of fistula, location, size, quality of the network tissue and history of repair (5). Overall success rate on the first attempt surgery is 70-97%, but it decreases until 40-85% when first attempt surgery was failed (6). Innovative application of biological graft is now needed for reconstructive surgery of rectovaginal fistula. The latest animal study has been published for intervention of graft in rectovaginal fistula repair. Aungst MJ et al found that there is no advantage if we use interposition graft for repair of rectovaginal fistula in rabbit models. They used polypropylene graft and porcine small intestine submucosa graft. But, they could potentially cause the longer inflammation stage, hematoma formation side

effect until graft rejection (7).

Human amniotic membrane (HAM) is a biomaterial from the inner layer of fetal membrane that has biocompatibility in wound healing (8). Some studies found the efficacy of HAM as biological dressing in skin ulcer, bone regeneration and other tissue engineering (9). HAM has some properties like anti-inflammatory, anti-angiogenetic, anti-fibroblastic, anti-microbial, and immune tolerance. It consists of several growth factors that control epithelial wound healing and limit the inflammatory reaction. Optimal epithelialization in vaginal and bladder reconstruction have been proven using HAM (10,11).

This study was conducted to evaluate systematically using HAM as bio-prosthesis in repairing rectovaginal fistula in animal model thus we can consider HAM for fistulectomy repair in clinical setting.

MATERIALS AND METHODS

Study search criteria and search strategy

We used the Preferred Reporting Items for Systematic Review and Meta-analysis (PRISMA) guideline to do our systematic review and meta-analysis. We analized animal studies from database Pubmed, Google Scholar, and Science Open. All search articles were published from 2010 to 2020. There were no language restriction. We used keyword ((human amniotic membrane) OR (HAM)) AND (rectovaginal fistula) AND ((animal study) OR (animal model)). Two authors (R.W. and E.M) independently reviewed all identified articles. Studies that met eligibility criteria and can be accessed in fulltext were included in this study. Any discrepancy was discussed by two authors.

Articles were selected based on the inclusion and exclusion criteria. The inclusion criteria were : (1) preclinical studies; (2) use of animal model; (3) application of HAM in rectovaginal fistula model; (4) research on healing score. The exclusion criteria were : (1) literature reviews, (2) conferences/abstracts only paper; (3) no analysis of healing score; (4) no full-text literature. We use PICOS format to examine the study eligibility criteria (Participants/animal and fistula models, Intervention, Comparison, Outcomes, Study Design) (Table 1). All selected articles were combined in forest plot as analyzed data.

Data extraction and analysis

Two authors (R.W., E.M) independently assessed the quality of included studies using the Systematic Review Centre for Laboratory Animal Experimentation (SYRCLE) risk of bias tools involving random group allocation, groups similar at baseline, blinded group allocation,

Table 1. Summary of the study characteristics of animal studies

	Participants		Intervention		Comparison	Outcome
Author	**Animal Models**	**Fistula Model**	**HAM preparation**	**Methods of insertion HAM**		**Observed Outcome**
Roshanravan R, et al, 2014	Female Dogs (8 mixed-breed female dogs weighing 23-27 kg with the age of 12-18 months) → 2 groups : Fistulectomy, Fistulectomy and HAM insertion	Iatrogenic recto-vagina fistula: sharp and blunt dissection 4 cm above anal verge → 14 F cathether was inserted to fistula to keep it open → observed 4 weeks	HAM was preserved in glutaraldehyde → frozen in -20°C → floated in normal saline 5-10 min at 24° C before insertion	HAM 2x2 cm was applied on the site of primary closure and fixed with Vicryl 3-0 → observed 6 weeks	Group with fistulectomy only. Catheter was removed and repair using Vicryl 3-0	Gross examination → no abscess formation, infection or pussy discharge. Microscopically: Healing score reviewed by pathologists (according to epithelization, collagenization, inflammation, ulcer, and necrosis), healing score was significantly higher in HAM group (p=0.029)
Hosseini SV,et al, 2017	New Zealand rabbits weighing 2-2.5 kg with the age of 6-8 months (12 rabbits) → 3 groups : Fistulectomy+HAM; Fistulectomy+Tachosil®+ HAM; and Fistulectomy only (control group)	A connection between vagina and rectum was made using electrocautery → feeding catheter inserted in fistula to keep it open and fixed with 3-0 prolene thread → observed 4 weeks	HAM was preserved in glutaraldehyde → frozen in -20°C → floated in normal saline before use for 5-10 min at 24°C. Group with Tachosil ® intervention was not analyzed in this review	HAM was applied on the site of primary closure and fixed with Vicryl 3-0 → observed 4 weeks	Group with fistulectomy only. Catheter was removed and repair using Vicryl 3-0	Gross examination → no abscess formation, infection or pussy discharge. Microscopically: Healing score reviewed by pathologists (according to epithelization, collagenization, inflammation, ulcer, and necrosis), no significantly different in healing score between groups (p=0.122)

random housing, blinded interventions, random outcome assessment, and reporting of drop-outs points. We also showed funnel plot graph representing the publication bias. Risk of bias was evaluated as low, high or unclear and recorded in Review Manager application.

We performed meta-analysis using Review Manager (RevMan v5.3, The Cochrane Collaboration Oxford, UK). Mean differences (MD) were calculated with 95% confidence intervals (CI) based on healing score from Pathologist review. The percentages of variation were assessed by I2 statistic and value I2 greater than 50% was considered heterogenous research. The results will be displayed in forest plot diagram.

RESULTS

Flow chart of study selection

Figure 1 shows details of the study selection. The primary search identified 12 articles. We screened title and abstract and got 3 eligible studies with full text format, but one of them is human study then we excluded it. Both articles were animal studies determining effects of human amniotic membrane (HAM) on rectovaginal fistula animal model (4,12). One study compared HAM and collagen biologic mesh on rectovaginal animal model.

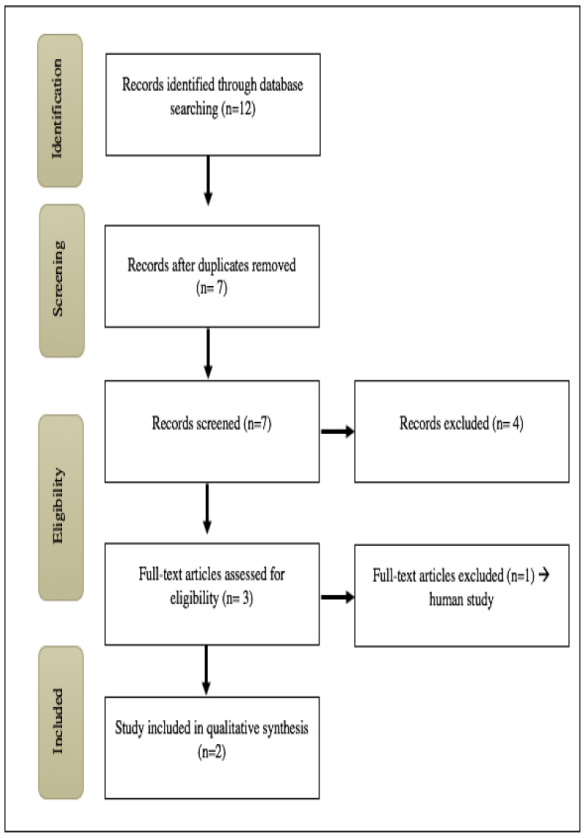

Figure 1: Flow diagram of the study selection

Characteristics of included studies

The two articles obtained were published in 2014 and 2017, respectively. All studies were preclinical experiments performed in dogs (12) and rabbits (4). Rectovaginal fistulas were made using surgical procedures. All procedures were done based on standards of laboratory biosafety guidelines with sterile environment. All studies describe their methods with initially doing the anesthesia procedure to the animals in lithotomy position and then followed by creation of rectovaginal septum by bimanual palpation. In Roshanravan's study rectovaginal fistula was made with sharp and blunt dissection 4 cm above the anal velge, but in Hosseini's study, it was made with electrocautery. Both then inserted cathether to keep it open. Animals were observed in laboratory cages for 4 weeks. Rectovaginal fistula formation was confirmed by a surgeon and veterinarian. After rectovaginal formation was confirmed they did fistulectomy repair (primary closure of rectovaginal surgery).

Both studies divided the animals into experimental and control group. In Hosseini's study they divided into 3 groups, first group was rabbits with HAM was applied on the site of primary closure and second group was Tachosil ® (collagen sponge patch) with HAM were applied in primary closure (not analyzed in meta-analysis), and the third group was control group. While in Roshanravan's study, they divided the study sample into 2 groups, first group was control group and the second group was dogs with simple closure with application of HAM in their site of primary closure. All control groups in both studies underdone repair only after foley catheter removed with Vicryl 3-0 interrupted stiches.

Observation was done for for 4-6 weeks after intervention process. The last procedure was termination of animals with potassium chloride (KCl) solution followed by excision of rectum and vagina from the whole body of animals. Rectum and vagina preparation were fixed in the formaldehyde 10% (formalin) solution. Pathologists in Department of pathology observed the gross and microscopic sample with blind name of samples. Histopathological findings was explained in healing score.

Study quality and publication bias

Figure 2 dan figure 3 shows the quality assessment of the included studies. Both studies show low risk bias to most variable of assessment, except for blinded intervention. In this animal studies of course no blinding for giving intervention for researcher, but it may happen to pathologist who review the histopathological results. But both studies did not mention it.

Publication bias from this meta-analysis is described in funnel plot. This funnel plot shows asymmetric graph that concluded that there is publication bias. This can happen because of few studied included in this review (Figure 4).

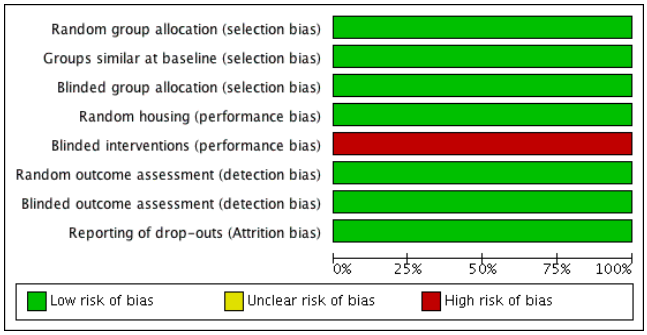

Figure 2: Risk of bias graph for each included study



Figure 3: Risk of bias summary for each included study

Outcome

Gross examination

In Hosseini's and Roshanravan's study, there is gross examination from rectum and vagina after given interventions. Hosseini et al observed gross changes after 4 weeks of intervention and found no abscess formation, infection, or pussy discharge . While Roshanravan et al observed for gross changes after 6 weeks of intervention by pathologist and everyday during fistula formation step by veterinarian. Roshanrayan et al found no abscess formation, infection or pussy discharge. But, one dog had a persistent fistulous tract.

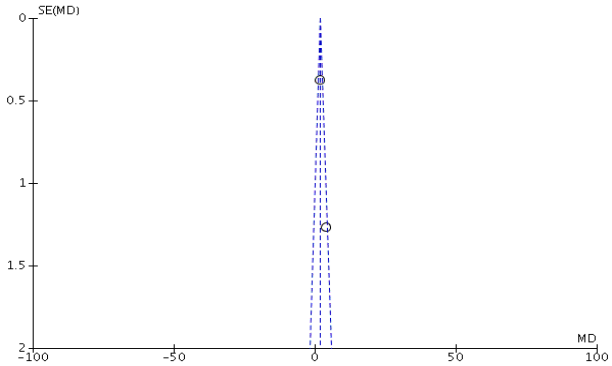

Figure 4: Funnel plot showing publication bias of included study

Wound healing score

Microscopic evaluation of rectum and vagina was using healing score. It is a scoring system for surgical wound healing based on histological examination, proposed by Grenhalg and Abramov (13). This score consists of 6 variables; epithelialization, collagenization, inflammation, neovascularization, necrosis and granulation tissue. Each variable can scored from 1 to 5. Hosseini et al found higher wound healing score in HAM group than control group, but they said that there was no significant difference. Roshanravan et al found the same results, in which HAM group had higher healing score than control group significantly.

In this meta-analysis we find wound healing score in HAM group is significantly different from wound healing score in control group, with mean difference (1.94[1.23, 2.66; p< 0.00001]) (Figure 5).

DISCUSSION

This study is the first systematic review and meta-analysis to evaluate the effects of HAM on rectovaginal fistula healing in animal studies. Our systematic review and meta-analysis including two animal studies in which gross results and microscopic results were reported. Microscopic results were described in wound healing score, an objective tools to evaluate wound healing after intervention histologically.

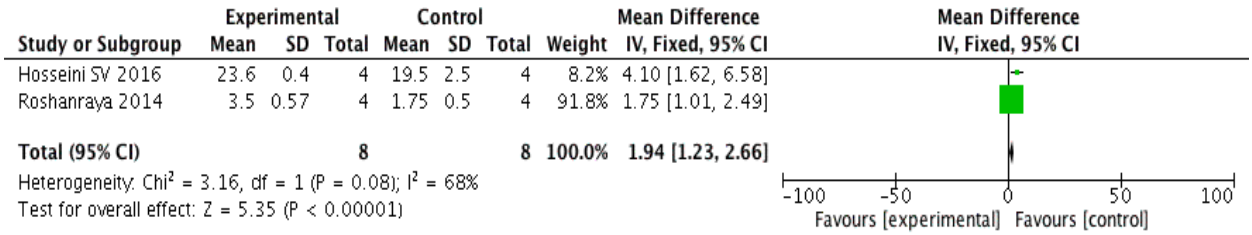

Figure 5: Healing score comparison of experimental group (HAM and fistulectomy) and control group (fistulectomy only group)

Innovative application of biological graft is now needed for reconstructive surgery of rectovaginal fistula due to high rate of recurrence after its first repair. A restrospective study from Fu J et al found that history of prior surgical repair is one of risk factor for failure rectovaginal repair. The fibroid tissue around the fistula and the prolonged inflammation made the operation more difficult. This study recommended an interval of more than 6 months to do reoperation to reduce the local inflammation and edema (14).

Animal study has proven the unsuccessful repair of biological graft (polypropylene and porcine small instestine submucosa graft) for rectovaginal fistula. The cause of this unsuccessful repair can be prolonged inflammation, graft rejection side effect and formation of hematoma (7). But, a case report from Berger, 2015 found that porcine-derived small intestinal submucosal extracellular matrix graft can repair rectovaginal fistula without any recurrence until 18 months. The lack of this case report is it just explains complicated patient (congenital anomaly of vagina) with repeated surgery, in which formed flaps can not produce optimal healing process (15).

Wound healing is a comprehensive process consisting of four phase, hemostatis, inflammation, proliferation and remodeling (16). Hemostasis consists of vascular constriction, platelet segregation, degranulation, and formation of fibrin. It happens immediately then followed by inflammation phase. This is initially with infiltration of neutrophil, monocyte, lymphocyte then differentiation to macrophage (17). Inflammation phase happens in day 1-4 (17). Proliferation has specific feature such as multiplication of cells and plenty connective tissue (16). The wound produces fibroblasts, keratinocytes and endothelial cells (16). The last phase is remodeling (day 21 to 2 years) (16). The gradual degradation of plenty extracellular matrix and the immature type III collagen followed by formation of mature type I collagen were feature of this remodeling phase. Any disruption on this phase may lead to profuse wound healing, prolonged inflammation and chronic wound (18).

Human amniotic membrane (HAM) or amnion is the innermost layer of fetal membranes having anti-microbial, anti-fibrosis, and anti-inflammatory properties. Its role in tissue engineering is well-known as it supports cell attachment, proliferation and differentiation. HAM does not affect their immunophenotype or differentiation properties in mesenchymal stem cells (19). In wound healing it proposed to have some roles, such as angiogenic, promotion of epithelization, inhibition of fibrosis and scar and also anti-inflammatory and antibacterial (20,21). There are many proposed mechanism of action how HAM can promote rapid wound healing and regeneration. First HAM inhibits cells of inflammation , then it reduces the pro-inflammatory cytokine and reduces chemotactic of neuthrophil. Besides, HAM has stimulation to some the growth factors, such as epidermal and keratinocyte growth factors. Formation of scar was prevented by decreasing TGF-1 and TGF-2 level (22).

HAM in recent publication was proved having role in reconstruction of wound healing. In Rafati M study HAM is an effective graft in stimulating the wound healing of perianal fistula in rabbits. There was no incident of wound infection, and no evidence of rejection (9). Uludag et al found HAM reduced inflammation and increase wound healing process. Besides, inflammatory cytokines suppressed, tissue growth factor and anti-inflammatory proteins expressed, and fibroblast activity and angiogenesis increased. The healing process in rabbits due is faster than humans then the external orifice was healed after 12 weeks of HAM application (23). Inflammation, proliferation and maturation are the most important phase in wound healing. Thus, any change on this phase will correlate to successful wound healing.

HAM can be used a scaffolds as it can be a tissue helping regeneration and reconstruction others tissues. For become a scaffold, HAM can be in acellular scaffolds or cell-seeded scaffolds. Actually the ideal scaffolds is in a form decellularized HAM. In this type the epithelial cells was removed from HAM in order to not interfere with new seeded on scaffold. While in cell-seeded scaffolds, the procedure of scaffolding start from processing intact HAM, sterilizing, and then preserving in glycerol, air-drying, freeze-drying, and incubation in trehalose.

Type of HAM used in these two included studies were preserved in glutaraldehyde and then frozen in -20°C. Based on Spoerl E preservation HAM in glutaraldehyde is to make a cross-linked collagen type IV component of HAM to increase the durability of the collagenous materials in patients. It also increase 175% in force-elongation measurement compared to fresh and by 76,8% compared to cryopreserved amnion. Glutaraldehyde is one of the strongest and effective cross-linkers and easily available. It also has potential advantage of lowering the risk for infection by transplant as it is used for sterilization purpose (24).

The limitation of this study is related to small size of relevant studies and animals. The small amount of relevant studies also effects the publication bias. But, this evidence can be preliminary for human study. We have to consider the holistic point of view for the application of HAM in such rectovaginal cases because of delivery trauma, abscess formation, Crohn's disease and others because it will be different cases if we compared with animal study, especially regarding to the different anatomical structure and immunity.

CONCLUSION

HAM is promising bio-material in wound healing of rectovaginal fistula. In animal studies, HAM showed better gross and histological outcome than fistulectomy repair only. We need further studies to evaluate the detailed effect of HAM application in rectovaginal fistula of human.

ACKNOWLEDGEMENT

This work is supported by Faculty of Medicine Universitas Airlangga, Surabaya, Indonesia.

REFERENCES

1. Tuma F., McKeown D.G., Al-Wahab Z. Rectovaginal Fistula. [Updated 2020 Nov 3], in: StatPearls [Internet]. Treasure Island (FL): StatPearls Publishing; 2020 Jan,. Available from: https://www.ncbi.nlm.nih.gov/books/NBK535350
2. Mar D.A., Serrano B.A, Morales C., Toro K., Burgos J. Long term success of complex recurrent rectovaginal fistula repair. Journal of Surgical Case Reports. 2019;3:1-4.
3. Nezhad F.T., Jalali R.M Karimi F. Women's experiences of rectovaginal fistula: an ethno-religious experience. BMC Women's Health. 2020; 20: 13.
4. Hosseini S.V., Aski M.H., Al Hurry A.M.A.H., Hassan A.R.K., Khazraei H., Zabangirfard Z., Zamani M. Simultaneous application of human amniotic membrane and Tachosil® in the repair of rectovaginal fistula in an animal model. Comp Clin Pathol. 2017; 26: 405-409.
5. El-Maadawy G., Salem N., Hefni A.H. Experience with different surgical procedures in rectovaginal fistula management. Trends Med. 2017; 12: 77-84.
6. Halverson A.L., Hull T.L., Fazio V.W., Church J., Hammel J., Floruta C. Repair of recurrent rectovaginal fistulas. Surgery. 2001: 753-758.
7. Aungst M.J., Bearss J.J., Lewis B.S., Fischer J.R., Bonhage M.R., Wright J. Interposition graft for rectovaginal fistula repair in the New Zealand white rabbit. Int Urogynecol J. 2010; 21: 737-742.
8. Najibpour N., Ahmed M.A.A.H, Bananzadeh A., Rezaianzadeh A., Kermani M.R., Gabash K.M., Tajali H., Hosseini S.V., Mehrabani D. The effect of human amniotic membrane as a covering layer on propylene mesh in decrease of adhesion after laparotomy in the rabbit. Comp Clin Pathol. 2016; 25: 131-135.
9. Rafati M., Hosseini S.V., Moradian F., Zamani M., Khazraei H., Mokhtan M. Human amniotic membrane effect on perianal fistula healing rabbits: an experimental study. Iran J Med Sci. 2018; 43(5):473-478.
10. Barski D., Gerullis H., Ecke T., Varga G., Boros M., Pintelon I., Timmermans J.P., Otto T. Human amniotic membrane dressing for the treatment of an infected wound due to an entero-cutaneous fistula: Case report. International Journal of Surgery Case Reports. 2018: 11-13.
11. Barski D., Gerullis H., Ecke T., Varga G., Boros M., Pintelon I., et al. Repair of a vesico-vaginal fistula with amniotic membrane-step 1 of the IDEAL recommendations of surgical innovation. Cent Eur J Urol. 2015; 68(4): 459-461.
12. Roshanravan R., Ghahramani L., Hosseinzadeh M., Mohammadipour M., Moslemi S., Rezaianzadeh A., et al. A new method to repair rectovaginal fistula: Use amniotic membrane in animal model. Adv Biomed Res. 2014; 3:114-124.
13. Abramov Y., Golden B., Sullivan M., Botros S.M., Miller J.J.R., Alshahrour A., Goldberg R.P., Sand P.K. Histologic characterization of vaginal vs. abdominal surgical wound healing in a rabbit model. Wound Repair Regen. 2007; 15(1):80–86.
14. Fu J., Liang Z., Zhu Y., Cui L., Chen W. Surgical repair of rectovaginal fistulas: predictprs of fistula closure. International Urogynecology Jounal. 2019; 30: 1659-1665.
15. Berger K., Faro J., Faro S. Repair of a recurrent rectovaginal fistula with a biological graft. Int Urogynecol J. 2015; 26: 1071-1073.
16. Guo S., DiPietro L.A.Factors affecting wound healing. J Dent Res. 2010; 89(3): 219-229.
17. Orsted H., Keast D., Lalande L.F., Megie M.F. Bascic principles of wound healing. Wound Care Canada. 2017; 9(2): 4-12.
18. Wang P.H., Huang B.S., Horng H.C., Yeh C.C., Chen Y.J. Wound healing. Journal of the Chinese Medical Assosiation. 2018; 81: 94-101.
19. Arrizabalaga J., Nollert M.U. The human amniotic membrane: a versatile scaffold for tissue engineering. ACS Biomaterials Sciend and Engineering. 2018: 1-35.
20. Ramuta T.Z., Kreft M.E. Human amniotic membrane and amniotic membrane-derived cells: How far are we from their use in regenerative and reconstruction urology?. 2018; 27(1): 77-92.
21. Fairbairn N.G., Randolph M.A., Redmond R.W. The clinical applications of human amniotic in plastic surgery. Journal of Plastic Reconstructive and Aesthetic Surgery. 2014; 1-14.
22. Chopra A., Thomas B.S. Amniotic membrane: a novel material for regeneration. J Biomim Biomater Tissue. 2013; 18(1): 1-8.
23. Uludag M., Citgez B., Ozkaya O., Yetkin G., Ozcan O., Polat N., et al. Effects of amniotic membrane on the healing of primary colonic anastomoses in the cecal ligation and puncture model of secondary peritonitis in rats. Int J Colorectal Dis. 2009;24:559-67.
24. Spoerl E, Wollensak G, Reber F, Pillunat L. Cross-linking of human amniotic membrane by glutaraldehyde. Opthalmic Res 2004; 36: 71-7.