ORIGINAL ARTICLE

The Efficacy of Fractional CO_2 Laser and Microneedling - Amniotic Membrane Stem Cell Conditioned Media for Photoaging

Maylita Sari[1], Menul Ayu Umborowati[1], Irmadita Citrashanty[1], Diah Mira Indramaya[1], Fedik A Rantam[2,3], M Yulianto Listiawan[1], Cita Rosita Sigit Prakoeswa[1,2]

[1] Dermatology and venereology Department, Faculty of Medicine, Universitas Airlangga – Dr. Soetomo Teaching Hospital, Surabaya 60132, Indonesia
[2] Dr.Soetomo General Academic Hospital / Faculty Of Medicine, Universitas Airlangga, Surabaya 60286, Indonesia
[3] Cell &Tissue Bank -Regenerative Medicine, Dr.Soetomo General Academic Hospital / Faculty Of Medicine, Universitas Airlangga Surabaya 60286, Indonesia

ABSTRACT

Introduction: The production of numerous growth factors is an essential feature of conditioned medium of amniotic membrane stem cells (AMSC-CM). Trans epidermal delivery is a new potential method for rejuvenation in photoaging skin. This study set out to compare the efficacy of fractional CO_2 laser (CO_2 laser) and microneedling for AMSC-CM in photoaging patients. **Methods:** An analytical method experiment was conducted on 60 women who were randomly classified into two groups; treated with AMSC-CM either after microneedling and CO_2 laser. Both groups were applied AMSC-CM topically for three times. The dynamic of clinical photoaging process was assessed by analysing wrinkle, pore, polarized spot, UV spot, and skin tone. **Results:** There was a statistically significant difference in delta polarized spot, UV spot, and pore of the third to first evaluation, between the two groups ($p< 0.05$). Besides, the median difference (delta) of polarized spot, UV spot, and pore parameter in the microneedling group was notably better than in the laser group. The median of skin tone of the fractional CO_2 laser plus AMSC-CM demonstrated statistically improvements between first to second evaluation (p=0.04). **Conclusion:** CO_2 laser and microneedling can accelerate efficacy of AMSC-CM trans epidermal delivery for the treatment of photoaging. The microneedling plus AMSC-CM is considered to be more effective for improving the pore, polarized spot, and ultraviolet spot.

Keywords: Trans epidermal delivery, AMSC-CM, Fractional CO_2 laser, Microneedling, Photoaging

Corresponding Author:
Cita Rosita Prakoeswa, SpKK (K)
Email: cita-rosita@fk.unair.ac.id
Tel: +231 5501609

INTRODUCTION

Skin aging is a multifaceted and progressive biological phenomenon that includes chronologic aging and photoaging. Aesthetic nonsurgical procedures to improve skin aging have also increased in recent years, prompted by the population's increasing age demands (1-4). Stem cell-based therapies with their growth factors' products are acknowledged as a breakthrough therapeutic strategy on tissue regeneration through a complex paracrine mechanism, along with their advanced direct cellular effect (5,6).

Amniotic membrane stem cells (AMSC) are better prospects for stem cell therapy and regenerative medication than other adult mesenchymal stem cells, considering the abundant, and efficient (6). Several recent studies have noticed that the secretion and production of various growth factors are essential for the conditioned medium of amniotic membrane stem cells (AMSC-CM). AMSC-CM can stimulate the synthesis of dermal collagen, proliferation, migration of dermal fibroblasts, and epidermal keratinocytes, improving wrinkles and facial defects caused by photoaging (4,6,7). In clinical practice, the advantage of the AMSC-CM is that there are no cells in AMSC-CM, thus lacking immunogenic and tumorigenic properties. Besides, AMSC-CM can be prepared during AMSC culture since there are plenty of invaluable sources of the cells (7,8).

Large molecular size of more than 20 k Da are most types of growth factors. Therefore, it is impossible for them to infiltrate the epidermis and generate pharmacologic effects. Trans epidermal drug delivery is a new potential method in dermatology on the cutaneous application efficacy of growth factors for skin rejuvenation. Hence, microneedling is one of the modality that creates micro injuries into the dermis to enhance the skin penetration of topical AMSC-CM (4,5,8). According to the previous clinical studies, microneedle combined with AMSC-CM demonstrated greater enhancements in the analysis of skin pore, wrinkle, polarized spot, and UV spot, compared with a combination of microneedle and normal saline (6).

Laser-assisted drug delivery is another evolving trans epidermal delivery system that may considerably increase the depth of penetration. Fractional CO_2 laser has now been considered the latest emerging concept to facilitate topical medication's deep delivery into the skin (8,9,10). The purpose of the fractional CO_2 laser is to create microthermal zone (MTZ) of ablation in the skin surrounded by slim layers of coagulated tissue. These MTZ channels accommodate access pathways for topical application to large drug molecules while reducing the restorative ®period after tissue damage by laser ablation (8,9). Fractional CO_2 laser has still been reported to develop multiple complications, particularly in Asian skin types (postinflammatory hyperpigmentation, prolonged erythema, skin swelling, infection, and scarring). Reducing the adverse reactions of fractional CO_2 laser while enhancing its therapeutic effect has shifted into a challenging interest in the dermatology field (7). Further research showed that laser-assisted trans epidermal delivery using topical AMSC-CM could improve skin pore and UV spot better than using the normal saline, and no serious adverse event has been reported (8).

Although the latest modality of trans epidermal delivery systems can improve the quality of skin aging treatment using AMSC-CM topical, the efficacy of the modality still requires further research. Therefore, this groundbreaking study set out to examine the effectiveness of fractional CO_2 laser-assisted plus AMSC-CM vs. microneedling plus AMSC-CM treatment for photoaging skin.

MATERIALS AND METHODS

Study design and participants

A 12-week prospective study was conducted to a total of 60 subjects at the Dermato Venereology outpatient clinic of Dr. Soetomo General Hospital Surabaya from November 2018 to May 2019. This clinical research was approved by the Ethical Committee Board of Dr.Soetomo General Hospital Surabaya. All subjects had signed informed consent before the participation.

The 60 subjects were recruited as participants from our dermatologist practice. Patients included in the study were aged between 40 and 65, had a visible indication of photodamaged skin from physical examination using the Glogau scale, had Fitzpatrick skin type IV-V, skin analyzed (Janus®, Korea), and willing to receive priming with 0.025% tretinoin cream for two weeks. Patients who were excluded for participation were those who had dermatologic conditions (eczema, wound on the face, herpes simplex, pigmentary disorders), diabetes mellitus, and autoimmune disorders. They were randomly divided into two groups, the fractional laser plus AMSC-CM group and microneedling plus AMSC-CM group, following a selection process derived from the Glogau scale and level of the pore, wrinkle, polarized spot, UV spot, and skin tone on Janus. Janus® examination of the first evaluation was undertaken before the first treatment, the second evaluation before the second treatment, and the third evaluation was 2 weeks (microneedling group) and 1 month (laser group) after the last treatment.

Preparation of the AMSC-CM

The AMSC-CM obtained from the Stem Cell Laboratory at the Institute of Tropical Diseases, Universitas Airlangga, and Biomaterial Regenerative Medicine Center, Dr. Soetomo Teaching Hospital was used in this study. The amniotic membrane obtaining procedures from the donor, the culture process of AMSCs, and the separating process of the AMSC-CM were performed legitimately under the international measures and protocols for collecting, processing, and storing human tissues and stem cell.

Procedures

Clinical improvement was assessed by Facial Skin Scope System Janus-II. The facial photos were analyzed using software to compare the patient's skin with those of the same age and profile. The multispectral photographic imaging was utilized, and the condition of the facial skin below the surface was measured in the skin analysis system. This digital imaging technology can capture textures for pore, wrinkle, polarized spot, UV spot, and skin tone parameters. Each analysis provided a percentage value. Analysis of all the parameters at each evaluation shows the magnitude of the value, if the value is smaller, it will indicate an improvement in the photoaging parameter (Figure 1).

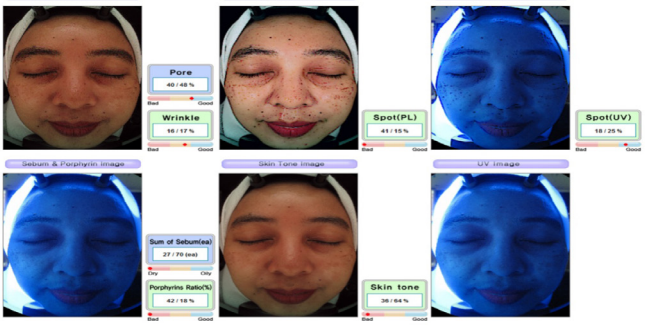

Figure 1: Skin analysis clinical photoaging (wrinkle, polarized spot, UV spot, skin tone, and pore) using Janus.

Next, for priming, the subjects were requested to apply 0.025% tretinoin cream for two weeks. Following the three-days break from the tretinoin cream, the treatments were started. The subject's face was then cleansed with an alcohol swab and soap, followed by topical and local anesthesia application using 2.5% lidocaine and 2.5% prilocaine cream. After around 45 minutes, the intervention group underwent treatment with fractional laser plus 3 mL of AMSC-CM, and the control group received treatment with microneedling plus 3 mL of AMSC-CM. Three treatments with an interval of a month for fractional CO_2 laser and two weeks for microneedling were performed for both groups.

The progress of photoaging parameters (pore, wrinkle, polarized spot, UV spot, and skin tone) for laser intervention was evaluated on the week 0, 4, and 12, while for microneedling, it was assessed on the week 0, 2, and 6 by the national board certified dermatologist. Moreover, the side effects's development following the treatment and the satisfaction levels were assessed via a questionnaire. The expected side effects were transient erythema and edema caused by the fractional laser and microneedle. The study intervention would be stopped, and the side effect's standard management would be applied if the subject experienced persistent side effects.

Statistical Analysis

The development in all parameters on both groups was evaluated by conducting the Mann-Whitney U test and unpaired T-test. The data were analyzed with SPSS version 21 software (SPSS Inc., Chicago, IL, USA). The significance level was arranged at $p < 0.05$.

Ethical Clearance

This study was approved by Research Ethics Committee, Dr. Soetomo Academic Hospital No. 0616/KEPK/Ix/2018.

RESULTS

The mean age of 60 subjects was 49.65±4.85. Fractional CO_1 laser-assisted plus AMSC-CM group comprised of 30 patients (all female). Microneedling plus AMSC-CM group consisted of 30 patients (all female). It can be perceived that no homogenous distribution of the variables of wrinkle, UV spot and skin tone ($p < 0.05$, Table I) was found.

The Glogau scale is considered the most applied photoaging assessment score, and its classification is based on the existence of wrinkles, pigment discoloration, and malignancy (Table II). In the fractional group, 17% were classified as Glogau type II, and 40% were Fitzpatrick skin type-V. In the microneedling group, 56.67% were considered Glogau type III, and 60% were Fitzpatrick skin type IV. It is shown that no statistically notable contrast was detected between the demographic data of the two groups (Table I). All subjects had completed the 12 weeks protocol, and no dropouts were found in this study. The mean and median delta (the result of the reduction between the second to first, third to first, and third to second evaluation) in the pore, wrinkle, polarized spot, UV spot, and skin tone of both groups are shown in Table III and IVU.

According on Janus® examination, it was found that there was a significant difference in polarized delta spot between the two groups from all evaluations ($p < 0.05$). The biggest distinction was found in the

Table I. Demography and baseline characteristics of the patients

Variable	Microneedling AMSC-CM (n=30)	Fractional CO_2 laser AMSC-CM (n=30)	Total (n=60)	p=0.05
Sex				
Male, n (%)	0	0		
Female, n (%)	30 (100)	30 (100)	60 (100)	
Range of Age				
40-44, n (%)	6 (20)	4 (13.3)	10 (16.67)	
45-49, n (%)	6 (20)	8 (26.7)	14 (23.33)	
50-54, n (%)	15 (50)	15 (50)	30 (50)	
55-59, n (%)	3 (10)	2 (6.7)	5 (8.33)	
60-64, n (%)	0 (0)	1 (3.3)	1 (1.67)	
Mean ±SD	49.20±4.817	50.10±4.923	49.65±4.850	p = 0.059
Glogau				
Category II	13 (43.33)	5 (17)	18 (30)	
Category III	17 (56.67)	25 (83)	42 (70)	
Mean ±SD	2.57±0.504	2.83±0.379	2.70±0.462	p= 0.000
Skin analyzer, Janus				
Mean (Rate) ± SD				
Pore	51.20 ±6.723	49.60 ±4.924		p = 0.200*
Wrinkle	11.90± 7.345	6.73± 2.586		p = 0.000
Spot (polarized)	32.63± 8.02	28.77± 6.527		p = 0.200*
Spot (ultraviolet)	14.87 ±8.569	7.77± 3.588		p = 0.000
Skin tone	39.33± 7.121	32.83± 2.972		p = 0.000

Table II. Glagou skin type (16)

Type of skin	Visible changes	Keratoses	Wrinkles	Age
Type I no wrinkles Early photoaging	Mild pigment changes	no	minimal	20-30 years of age
Type II wrinkles in motion-mimic Early to moderate photoaging	Early senile lentigo	Palpable but not visible	Parallel smile lines beginning to appear side of the mouth	Late 30's or 40's
Type III Wrinkles at rest Advanced stage photoaging	Dischromation obvious	visible	At rest	At the age of 50 and older persons
Type IV Expressed photoaging	Yellow-green color	Precedes malignant skin lesions	A fully lined, has normal skin	The 6th or 7th decade

difference between the mean value of the third to first evaluations. Where the microneedling group showed better improvement because the mean polarized delta spot evaluation showed a negative result (Table III). A negative result indicates a decrease/ improvement in the clinical parameters of photoaging.

The median delta UV spot, delta skin tone, and delta pore between third to first evaluation was notably different ($p < 0.05$) in both groups. Compared with the fractional CO_2 laser AMSC-CM group, the microneedling AMSC-CM group showed better improvement in the median delta UV spot - 2.50 (-25-6) from two weeks after the final treatment session to before the first treatment (Table 4). The median difference (delta) of pore and skin tone between third to second evaluation in both groups were also statistically different (p= 0.00 and p = 0.01). Similarly, subjects treated with microneedling plus AMSC-CM demonstrated better improvement of the median delta pore parameter than the fractional CO_2 laser group of -2.00 (-9 – 8) between third evaluation to second evaluation. Delta skin tone parameters also showed significant differences in the 2 groups, although the fractional CO_2 laser and microneedling groups both provided improvements (Table IV).

Table III. Polarized delta spot analysis between microneedling AMSC-CM and fractional CO_2 laser AMSC-CM groups

Polarized Delta Spot	Group	Mean (SD)	p	Mean Difference (CI 95%)
Evaluation 2-1	Microneedling (n=30)	-1.07 (5.06)	0.01*	-3.30 (-5.82 - - 0.78)
	Fractional CO_2 laser (n=30)	2.23 (4.67)		
Evaluation 3-1	Microneedling (n=30)	-1.07 (6.55)	0.00*	-6.20 (-9.36 - -3.04)
	Fractional CO_2 laser (n=30)	5.13 (5.64)		
Evaluation 3-2	Microneedling (n=30)	0.00 (4.64)	0.02*	-2.90 (-5.34 - - 0.45)
	Fractional CO_2 laser (n=30)	2.90 (4.81)		

Unpaired T-test

Table IV. p values of significance of the improvement in homogenous parameter of photoaging

Parameter	Groups	Median (Minimum-Maksimum)	p
Delta wrinkle evaluation 2-1	Microneedling (n=30)	-1.00 (-19-11)	0.09
	Fractional CO_2 Laser (n=30)	1.00 (-5-7)	
Delta wrinkle evaluation 3-1	Microneedling (n=30)	-1.00 (-21-16)	0.05
	Fractional CO_2 Laser (n=30)	1,00 (-4-16)	
Delta wrinkle evaluation 3-2	Microneedling (n=30)	0.50 (-11-17)	0.26
	Fractional CO_2 Laser (n=30)	1.00 (-4-19)	
Delta UV spot evaluation 2-1	Microneedling (n=30)	-1.50 (-22-11) *	0.03*
	Fractional CO_2 Laser (n=30)	1.00 (-8-11) *	
Delta UV spot evaluation 3-1	Microneedling (n=30)	-2.50 (-25-6) *	0.01*
	Fractional CO_2 Laser (n=30)	1.00 (-8-13) *	
Delta UV spot evaluation 3-2	Microneedling (n=30)	0.00 (-17-9)	0.21
	Fractional CO_2 Laser (n=30)	0.00 (-10-8)	
Delta skin tone evaluation 2-1	Microneedling (n=30)	0.00 (-18-15)	0.39
	Fractional CO_2 Laser (n=30)	-1.00 (-4-5)	
Delta skin tone evaluation 3-1	Microneedling (n=30)	-1.00 (-16-13) *	0.04*
	Fractional CO_2 Laser (n=30)	0.00 (-8-6) *	
Delta skin tone evaluation 3-2	Microneedling (n=30)	-1.00 (-16-15)*	0.01*
	Fractional CO_2 Laser (n=30)	0.00 (-4-5) *	

CONTINUED

Table IV, p values of significance of the improvement in homogenous parameter of photoaging (CONT.)

Parameter	Groups	Median (Minimum-Maksimum)	p
Delta pore evaluation 2-1	Microneedling (n=30)	-1.00 (-6-28)	0.46
	Fractional CO_2 Laser (n=30)	-1.00 (-6-8)	
Delta pore evaluation 3-1	Microneedling (n=30)	-2.00 (-10-24) *	0.00*
	Fractional CO_2 Laser (n=30)	3.00 (-4-12) *	
Delta pore evaluation 3-2	Microneedling (n=30)	-2.00 (-9-8) *	0.00*
	Fractional CO_2 Laser (n=30)	3.50 (-1-10) *	

Mann Whitney Test

DISCUSSION

The evolution of photoaging could be influenced by age, skin, lifestyle, and ethnicity associated with UV exposure. A prior study stated that women seek rejuvenation treatment more regularly compared to men (6). In the current study, all subjects were women, and the majority of the subjects were aged between 45 and 49. Management of skin aging represents a challenging dermatological condition. Since the most effective treatment has not been obtained yet, a multimodal approach is required to obtain desirable outcomes. In order to acquire more potentially optimizing results with minimum unpropitious effects, new combination methods are preferred (5).

Stem cell-based therapy is one of the alternatives to the most advanced skin rejuvenation. In particular, AMSC-CM secretes numerous growth factors such as basic fibroblast growth factor (bFGF), hepatocyte growth factor, keratinocyte growth factor, transforming growth factor b1 (TGF-b1), and vascular endothelial growth factor that mediate proliferation, migration, and a variety of therapeutic effects of skin regeneration (7,11). Conditioned media from mesenchymal stem cells can accelerate wound closure of keratinocytes and human dermal fibroblasts and elevate collagen synthesis in vitro. It is also revealed that matrix metalloproteinase-1 (MMP-1) expression by UVA is downregulated, and procollagen 1A expression is increased through treatment with amniotic fluid-derived stem cells-conditioned media (12,13). Previous studies proposed that photoaging acquires pathological processes like wound healing, where dermal fibroblasts are the significant roles through the synergy with other cells, including fat and mast cells (14). So conditioned media derived from mesenchymal stem cells can be used for the treatment of photoaging.

A transdermal delivery system, such as microneedling and fractional ablative laser, is required for those growth factors' cutaneous application since they are large molecular size and hydrophilic [5]. Seo et al., in their article, discovered that stem cell-secreted factors could infiltrate the dermis through the damaged skin barrier affected by fractional radiofrequency (7). According to the results of previous works, utilizing fractional erbium laser and topical AMSC-CM can enhance the effects to improve skin pore and spot in aging skin. There are no prolonged downtime or serious adverse events using laser-assisted transdermal delivery and AMSC-CM. Hence, it can be a safe treatment option for facial rejuvenation (8).

Many studies have suggested that fractional CO_2 laser can notably refine wrinkles and skin texture (7). This research has found that following three laser-assisted AMSC-CM treatment, the skin tone was statistically significant improvement. Nevertheless, the wrinkle were not markedly different between pre and posttreatment with laser-assisted AMSC-CM delivery (Table V). Prior studies have not been able to evaluate the use of AMSC-CM with fractional laser in controlling skin aging. However, Zhou et al. found out that topical application of adipose-derived stem cell conditioned media (ADSC-CM) can improve the effectiveness of fractional CO_2 laser treatment of skin rejuvenation, simultaneously quicken regeneration, and diminish downtime post lasers, such as edema and erythema (7). Oni et al. also explained in vitro study that ADSC could be delivered transdermally in a patient who has undergone fractional laser pretreatment (11).

Similar to the current findings, a prior study by Zhou et al. noticed that growth factors secretion AMSC was observed to decrease hyperpigmentation after fractional CO_2 laser. The enlightening effectiveness of

Table V. Analysis of skin tone and wrinkle parameters in fractional CO_2 laser group (intrgroup)

Fractional CO_2 laser group		Median (Min-Max)	p Friedman	p post hoc Wilcoxon
Wrinkle	Evaluation 1	7.00 (2-14)	0.07	Visit 1vs2 = 0.33
	Evaluation 2	7.00 (2-13)		Visit 1 vs 3 = 0.06
	Evaluation 3	7.00 (4-23)		Visit 2 vs 3 = 0.04
Skin tone	Evaluation 1	33.00 (27-41)	0.04*	Visit 1 vs 2= 0.04*
	Evaluation 2	32.00 (26-39)		Visit 1 vs 3= 0.24
	Evaluation 3	32.00 (27-39)		Visit 2 vs 3= 0.08

Friedman

growth factors in AMSC-CM was through restraining the synthesis of melanin and tyrosinase activity in a dose based on the process and downregulation of the expression of melanogenic enzymes, like tyrosinase-related protein-1 and TGF-b1 (7). It can be seen from the findings that 2 weeks and 1 month after the last session, postinflammatory hyperpigmentation was not found between the two groups. UV and polarized spots experienced a better improvement in microneedling plus AMSC-CM based on clinical parameters using Janus skin analysis, compared to the intervention group (fractional CO_2 laser AMSC-CM). Laser-assisted drug delivery in the current study employs three steps: breaking down the skin barrier, discretionary use of laser for therapeutic effect, and delivering the AMSC-CM through laser channels to improve the therapeutic effect further (10). Moreover, all subjects' skin type in this study was IV-V. This situation can affect the effectiveness of laser-assisted AMSC-CM topical for spot improvement in skin aging.

The fractional laser has shown identical advantages to conventional lasers, including elevated permeation, prolonged flux, and topical agents' depth, with faster healing time. It is suggested that the frequency of skin irritation, erythema, edema, dyspigmentation, and prolonged postoperative recovery were relatively low when using a fractional CO_2 laser. However, recovery downtime is usually able to be detected (9). As it is shown in our study, the lower the fluence used, the fewer densities were used for multiple session treatments, although it might be one aspect that could limit patient compliance. All participants experienced expected effects posttreatment and no serious adverse effects. All patients also experienced mild transient erythema.

Domyati et al. confirmed histologically that the combination of amniotic fluid mesenchymal stem cell-conditioned media and microneedling could increase dermal collagen, normal elastin density, and arrangement (5). Another study implied that using AMSC-CM combined with microneedling for photoaging has shown significant improvement in clinical aging signs (pore, wrinkle, polarized spot, UV spot) compared to microneedling with normal saline (6). The diffusion mechanism is followed by drug delivery through the topical course. The skin is tentatively interrupted in the microneedle drug delivery system. A microneedle device may consist of arranging many microneedles in arrays on a diminutive patch to give a therapeutic response through an adequate amount of drug (15).

The results strongly suggest that microneedling and fractional CO_2 laser can improve the effect of topical application of AMSC-CM and hasten the downtime after microneedling and fractional laser treatment for skin rejuvenation. The present study was subject to few patients, difficult in getting homogenous subjects, and no long-termed evaluation. Further evaluation in more extensive studies and a more prolonged follow-up duration are compulsory to validate the findings. Despite its limitation, this research is considered to be the first study that has evaluated and compared the efficacy of fractional laser CO_2 (Fraxis®, Korea) plus AMSC-CM delivery and microneedling (MRS Herca®, Spain) plus AMSC-CM for skin photoaging.

CONCLUSION

The fractional CO_2 laser and microneedling can accelerate the efficacy of transdermal AMSC-CM delivery for the skin aging treatment. Taken together, the findings indicate that microneedling plus AMSC-CM was better photoaging parameters for developments in the pore, polarized spot, and ultraviolet spot. However, the skin tone demonstrated improvement in both fractional laser CO_2 AMSC-CM and microneedling.

ACKNOWLEDGEMENT

This work is supported by research grant from Airlangga University, Surabaya, Indonesia.

REFERENCES

1. Serdar ZA, Tatliparmak A. Comparison of efficacy and safety of fractional radiofrequency and fractional Er:YAG laser in facial and neck wrinkles: six year experience with 333 patients. Dermatologic Therapy. 2019;32: e13054.
2. Choi JS, Cho WL, Choi YJ, Kim JD, Park HA, Kim SY, et al. Functional recovery in photo damaged human dermal fibroblast by human adipose derived stem cell extracellular vesicles. Journal of Extracellular Vesicles. 2019; 8: 1565885.
3. Li L, Ngo HTT, Hwang E, Wei X, Liu Y, Liu J, et al. Conditioned medium from human adipose derived mesenchymal stem cell culture prevents UVB induced skin aging in human keratinocytes and dermal fibroblasts. Int.J Mol Sci. 2020;21:49.
4. Lee HJ, Lee EG, Kang S, Sung JH, Chung HM, Kim DH. Efficacy of microneedling plus human stem cell conditioned medium for skin rejuvenation: A randomized, controlled, blinded split face study, Ann Dermatol. 2014; 26:.5
5. Domyati ME, Moftah NH, Nasif GA, Ragaie MH, Ibrahim MR, Ameen SW. Amniotic fluid derived mesenchymal stem cell products combined with microneedling for acne scars: A split face clinical, histological, and histometric study. J Cosmet Dermatol. 2019;00:1-7.
6. Prakoeswa CRS, Pratiwi FD, Herwanto N, Citrashanty I, Indramaya DM, Murtiastutik D, et al. The effects of amniotic membrane stem cell conditioned medium on photoaging. Journal of Dermatological Treatment. 2018; 1530438.
7. Zhou BR, Zhang T, Jameel AAB, Xu Y, Guo SL, Permatasari F, et al. The effivacy of conditioned

media of adipose derived stem cells combined with ablative carbon dioxide fractional resurfacing for atrophic acne scars and skin rejuvenation. Journal of Cosmetic and Laser Therapy. 2016; 1114638.
8. Widianingsih NPS, Setyaningrum T, Prakoeswa CRS. The efficacy and safety of fractional erbium YAG laser combined with topical amniotic membrane stem cell (AMSC) metabolite product for facial rejuvenation: A controlled, split face study. Dermatology Reports. 2019; 11(s1); 8036.
9. Sklar LR, Burnett CT, Waibel JS, Moy RL, Ozog DM. Laser assisted drug delivery: A review of an evolving technology. Lasers in Surgery and Medicine 2014;46:249-62
10. Waibel JS, Rudnick A, Shagalov DR, Nicolazzo DM. Update of ablative fractionated lasers to enhance cutaneous topical drug delivery. Adv Ther. 2017; 34: 1840-9.
11. Oni G, Lequeux C, Cho MJ, Zhang D, Lezcano E, Brown SA, et al. Transdermal delivery of adipocyte derived stem cells using a fractional ablative laser. Aesthetic Surgery Journal. 2013; 33(1): 109-16.
12. Huh MI, Kim MS, Kim HK, Lim JO. Effect of conditioned media collected from human amniotic fluid derived stem cells (hAFSCs) on skin regeneration and photoaging. Tissue Engineering and Regenerative Medicine. 2014; 11:2.
13. Reilly MJ, Cohen M, Hokugo A, Keller GS. Molecular effects of fractional carbon dioxide laser resurfacing on photodamaged human skin. Arch Facial Plast Surg. 2010; 12(5): 321-5.
14. Xu X, Wang HY, Zhang Y, Liu Y, Li YQ, Tao K, et al. Adipose-derived stem cells cooperate with fractional carbon dioxide laser in antagonizing photoaging: a potential role of Wnt and β catenin signalling. Cell & Bioscience. 2014; 4:24.
15. Waghule T, Singhvi G, Dubey SK, Pandey MM, Gupta G, Singh M, et al. Microneedles: A smart approach and increasing potential for transdermal drug delivery system. Biomedicine & Pharmacotherapy. 2019;109:1249-58.
16. Stojiljkovic D, Pavlovic D, Arsic I. Oxidative stress, skin aging, and antioxidant therapy. Acta Facultatis Medicae Naissensis. 2014; 31 (4): 207-217.