CASE REPORT

Peritoneal-Pleural Communication Demonstrated by Peritoneal Scintigraphy

Mohammad Fitri Khalil[1,2], Khadijah Abdul Hamid[1], Fadzilah Hamzah[2]

[1] Oncological and Radiological Sciences Cluster, Advanced Medical and Dental Institute, Universiti Sains Malaysia, 13200 Kepala Batas, Penang, Malaysia
[2] Department of Nuclear Medicine, Penang General Hospital, Jalan Residensi, 10990 Penang, Malaysia

ABSTRACT

For the past few decades peritoneal scintigraphy had been used for various indication as it is simple, widely available, and relatively safe. The indications for performing this scan include evaluation of peritoneal distribution for planned intraperitoneal chemotherapy, to detect pleural-peritoneal or peritoneal-scrotal communications, to assess peritoneal shunt patency and to evaluate problems that might occur with peritoneal dialysis. We report a case of a young gentleman with end stage renal failure recently was started on continuous ambulatory peritoneal dialysis (CAPD), presented with shortness of breath. Chest x-ray showed right pleural effusion and the pleural tap suggested the fluid originated from the peritoneal cavity. Peritoneal scintigraphy was done to confirm the movement of fluid from peritoneal to pleural cavity. This case illustrates the importance of peritoneal scintigraphy in confirming peritoneal-pleural communication.

Keywords: Peritoneal scan, Peritoneal-pleural communication, Dialysis, Pleural effusion

Corresponding Author:
Khadijah binti Abdul Hamid, MMed (Nuclear Med.)
Email: khadijah@usm.my
Tel: +604-5622414

INTRODUCTION

Continuous ambulatory peritoneal dialysis (CAPD) is widely used for the long-term management of end stage renal failure since the year 1976. It is mainly used for those patients who are unable or unwilling to undergo haemodialysis or renal transplant, patient with cardiovascular disease especially in heart failure, old patient, those who are at risk of adverse effect of systemic heparin, severe hypertension and those who have exhausted their vascular access. The goals of peritoneal dialysis are removing toxic substances and metabolic wastes, reverse the symptom of uraemia, re-establish normal fluid and electrolyte balance and maintaining a positive nitrogen balance. Although it offers several advantages over haemodialysis, there have been several recognized complications. As it is mainly a long term form of usage, it requires intact anatomical integrity of the peritoneal cavity. As intraabdominal pressure increases due to the instillation of intraperitoneal fluid, it predisposes the patient to leaks and herniation through defects in the abdominal wall. Complication related to usage of peritoneal dialysis such as pleural effusion (due to peritoneal-pleural communication), scrotal swelling (peritoneal-scrotal communication), hernia incarceration and recurrent peritonitis, which all leads to temporary switching to haemodialysis. Investigations that can be done are peritoneal scintigraphy, computer tomography scan (CT scan) and peritoneography with iodinated contrast.

CASE REPORT

A 23-year-old gentleman with history of end stage renal failure for four years was on 3 weekly haemodialysis using arteriovenous fistula. However, 3 months ago, the arteriovenous fistula was infected and non-functioning. Temporarily, he was using perm catheter (permcath) for haemodialysis. Trial of re-inventing the arteriovenous fistula failed after 4 attempts. Due to exhausted vascular access, he was started on CAPD.

However, about two weeks after starting CAPD, he developed gradual onset of shortness of breath associated with cough and low-grade fever. A chest x-ray was done and revealed massive right pleural effusion (Fig. 1A). He was admitted to Penang General Hospital and antibiotics were given. CAPD was withheld and he was switched to haemodialysis using internal jugular vein catheter temporarily. Pleural tapping was done and showed transudate with glucose level of 18.3 mmol/L which was almost similar to peritoneal fluid's glucose level. His serum blood glucose was only 5.0 mmol/L.

A repeat chest x-ray was done after a few days which

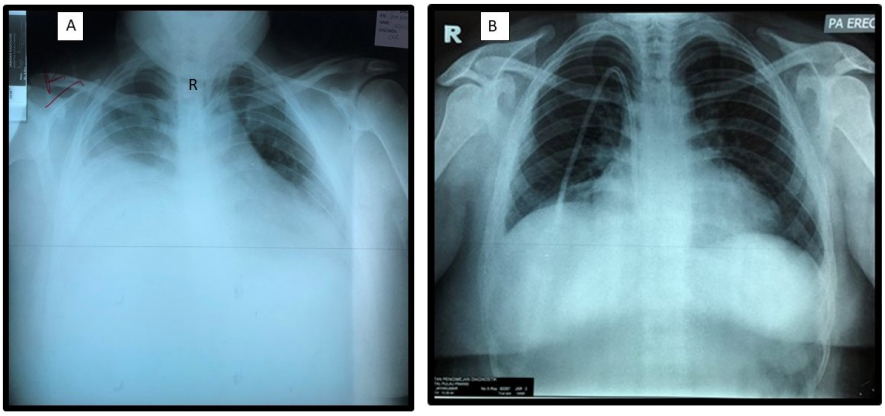

Figure 1: (A) massive right pleural effusion in the PA view of the chest x-ray. (B) resolution of right pleural effusion in the PA view of a chest x-ray

showed resolution of the right pleural effusion (Fig. 1B). He was referred to nuclear medicine department for the investigation of the right pleural effusion.

Tc-99m Nanocolloid (119 MBq) was mixed with 2.0 L of dialysate fluid. The mixture was slowly infused into the peritoneal cavity through Tenckhoff catheter. Dynamic imaging (1 minute per frame) of abdomen and lower part of thorax was acquired for 30 minutes. The dynamic imaging was compressed into 12 frames. Static images of anterior, posterior, and lateral of abdomen and thorax was acquired after 30 minutes and delayed imaging was done 2 hours later.

Dynamic imaging showed accumulation of tracer in the peritoneal cavity (Fig. 2). Static images were done at 30 minutes (200K count each) showed faint uptake of tracer in the right hemithorax (Fig. 3A). Delayed static images at 2 hours showed a more prominent uptake of tracer at right hemithorax (Fig. 3B). There was no abnormal tracer accumulation seen in the left thoracic cavity or elsewhere in the body. These findings were suggestive of peritoneal fluid leakage into the right thoracic cavity.

CAPD for this patient was further withhold until correction of the leakage is done. Meanwhile he continued haemodialysis using temporary catheter in the internal jugular vein.



Figure 2: Dynamic imaging shows accumulation of tracer in the peritoneal cavity during the first 30 minutes of the study. XS-xiphisternum ASIS-anterior superior iliac spine

DISCUSSION

One of the primary complicating factors affecting the long-term use of CAPD is loss of the anatomic integrity of the peritoneal cavity. Although some of the complication can be detected clinically, it is often necessary to confirm using diagnostic imaging.

Pleural effusion or hydrothorax because of pleuro-peritoneal communication is uncommon, occurs in approximately 2% of CAPD patients (1). It is a well-recognized complication of peritoneal dialysis. Typically, patient may develop pleuritic chest pain and shortness of breath. It is caused by migration of fluid into the pleural space via pleuroperitoneal fistula. The reported incidence of pleural effusion in CAPD patient is about 1.6% (2). There is a predominance of right sided pleural effusion, as the defect are usually right sided and congenital (1). Most of the cases happened within the first 30 days of starting the peritoneal dialysis and about 25% of them are asymptomatic (3).

The diagnosis of hydrothorax requires a combination of biochemical and imaging modalities. Pleural fluid biochemistry analysis will usually reveal a transudate with a high glucose concentration. The pleural fluid glucose is affected by the dialysate composition, and generally accepted that a glucose level of more than 16.5 mmol/L or greater than the serum glucose level is consistent with hydrothorax (4).

Imaging modalities such as computerized tomography scan (CT scan) and MRI are less frequently used compared to peritoneal scintigraphy. CT scan requires contrast administration which is not the first choice for renal failure patients as it is nephrotoxic and might cause fluid overload. Peritoneal scintigraphy using Tc-99m-DTPA has a sensitivity of approximately 50% (5). Radiotracer that are usually used includes Tc-99m Sulfur Colloid, Tc-99m Nanocolloid and Tc-99m Macro-aggregated Albumin (MAA) as they do not diffuse through peritoneal surfaces. These radiopharmaceuticals will stay below the diaphragm unless there is a connection such as pleural or scrotal communications.

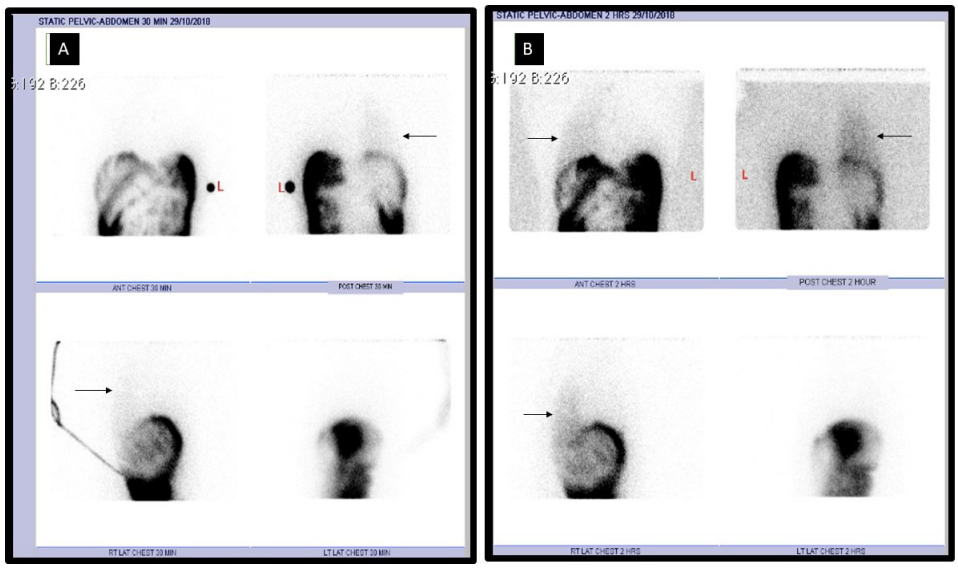

Figure 3: (A) static imaging at 30 minutes of the study. There is faint uptake of tracer in the right hemithorax, seen in the posterior and right lateral views (shown by the black arrows). (B) static imaging at 2 hours of the study. There is more prominent uptake of tracer in the right hemithorax, seen in the anterior, posterior, and right lateral views (shown by the black arrows)

CONCLUSION

In conclusion, peritoneal scintigraphy is very useful, less invasive, and a safe procedure for the evaluation of pleural effusion to demonstrate peritoneal-pleural communication in patients with end-stage renal failure who are using CAPD method of dialysis.

ACKNOWLEDGEMENTS

Parts of this study were presented in the abstract form in the 2nd AMDI International Oncology and Medical Physics Symposium (IOMPS), Penang, Malaysia, March 1-3, 2019. We would like to thank Penang General Hospital and Advanced Medical and Dental Institute for the collaboration in producing this case report.

REFERENCES

1. Chow KM, Szeto CC, Li PKT. Management Options for Hydrothorax Complicating Peritoneal Dialysis [Internet]. Vol. 16, Seminars in Dialysis. John Wiley & Sons, Ltd; 2003 [cited 2021 May 21]. p. 389–94. Available from: https://onlinelibrary.wiley.com/doi/full/10.1046/j.1525-139X.2003.16080.x
2. Nomoto Y, Suga T, Nakajima K, Sakai H, Osawa G, Ota K, et al. Acute hydrothorax in continuous ambulatory peritoneal dialysis a collaborative study of 161 centers. Am J Nephrol [Internet]. 1989 [cited 2021 May 21];9(5):363–7. Available from: https://www.karger.com/Article/FullText/167997
3. Bae EH, Kim CS, Choi JS, Kim SW. Pleural Effusion in a Peritoneal Dialysis Patient. Chonnam Med J. 2011;47(1):43.
4. Leblanc M, Ouimet D, Pichette V. Dialysate leaks in peritoneal dialysis. Semin Dial. 2001;14(1):50–4.
5. Pankaj P, Pathak V, Sen IB, Verma R, Bhalla AK, Marwaha A, Pandey S: Use of radionuclide peritoneography in the diagnosis of pleuroperitoneal communication as a complication of continuous ambulatory peritoneal dialysis. Ind J Nucl Med 2005, 20:4-8.