

An Adult With Thumb Sign In The Lateral Neck Radiograph

Irfan Mohamad*,¹ Mohd Syafwan Mohd Soffian,¹ Amran Mohamad²

¹Department of Otorhinolaryngology-Head & Neck Surgery, School of Medical Sciences, Universiti Sains Malaysia Health Campus, 16150 Kota Bharu, Kelantan, Malaysia.

²Department of Otorhinolaryngology, Hospital Sultanah Nur Zahirah, Kuala Terengganu, Terengganu, Malaysia.

ABSTRACT

Acute epiglottitis though relatively common in pediatric patients as compared to adults, present with almost similar clinical presentations. They include voice change, difficulty or painful swallowing and sometimes with upper airway obstruction. Physical finding of swollen epiglottis is difficult to be obtained owing to the danger of introducing laryngeal mirror into the oropharynx as to avoid contact spasm. The diagnostic thumb sign appearance on lateral neck radiograph is considered pathognomonic of epiglottitis. We report a case of an adult with clinical features and radiological finding of an acute epiglottitis, which did not resolve with antibiotic treatment. Subsequent imaging confirmed the presence of an abscess in the epiglottic mucosa.

Keywords: Epiglottis, Thumb sign, Epiglottitis, Adult, Abscess

INTRODUCTION

Epiglottic abscess is uncommon sequelae of acute epiglottitis, occurring in fewer than 4% of cases following acute epiglottitis¹. It is a serious life-threatening disease because of its potential for very rapid airway compromise and carries a high mortality rate². The diagnosis of epiglottic abscess is often difficult and easily misdiagnosed with other more common infections.³

CASE REPORT

A 64-year-old man with known history diabetes mellitus presented with sore throat, dysphagia, and change in voice for 3 days duration. There was no history of accidental fishbone ingestion. Clinical findings revealed he was febrile and talking with muffled voice. There was no dyspnea or stridor. Oral cavity showed no palatal bulge, with normal tongue and floor of mouth appearance. Posterior pharyngeal wall was inflamed. Neck examination was normal. Laryngoscopy was withheld by the attending medical officer at this time in view of acute epiglottitis was suspected.

Lateral neck radiograph obtained showed thumb sign appearance (Figure 1). The patient was treated as acute epiglottitis. He was started on parenteral antibiotics intravenous Ceftriaxone 2 g daily, dexamethasone 8 mg tds and regular adrenaline inhalations. He was also given humidified oxygen and was kept under close monitoring. After 2 days, evaluation using fiberoptic laryngoscopy was done as the patient showed no improvement (Figure 2). The epiglottis was congested covered with thick whitish slough on the left side. Laryngeal lumen was narrowed by almost 50%. An urgent contrast-enhanced computed tomography (CT) scan of the neck was obtained (Figure 3a & 3b). It confirmed the diagnosis of epiglottic abscess.

The patient was taken into the theatre for an emergency drainage. The airway was secured with fiberoptic nasotracheal intubation. A tracheostomy set was placed ready at the bedside. Incision and drainage was performed via a suspended direct laryngoscopy. The pus drained was minimal and the amount was less than 5cc.

He was successfully extubated on day 2 post operation after positive 'cuff leak test'. On the next day, a repeat fiberoptic laryngoscopy showed the resolution of the edema. He was discharged home on day 7 post operation. On follow up after one week, he was well with no residual symptom. There was no hoarseness and laryngoscopy showed normal findings except minimal slough on the epiglottis. He was last seen after 2 months with complete recovery.

*Corresponding author: Assoc. Prof. Dr Irfan Mohamad
irfankb@usm.my

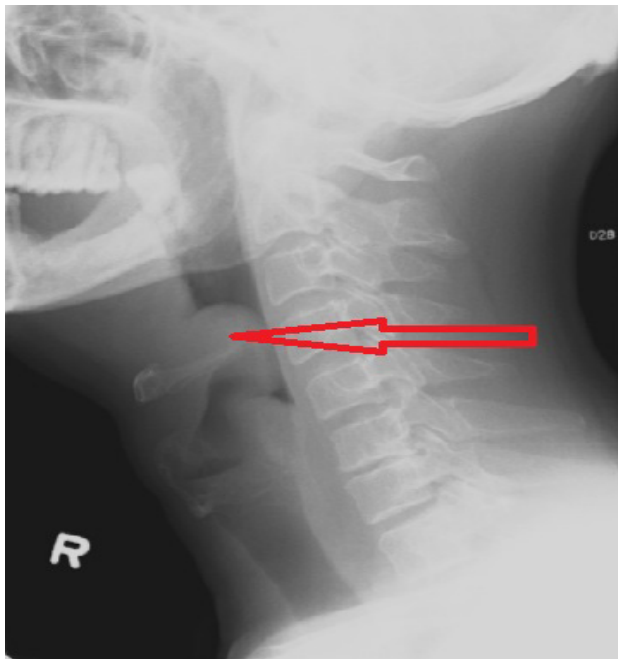


Figure 1: Lateral soft tissue neck radiograph showing a swollen epiglottis with typical thumb sign.

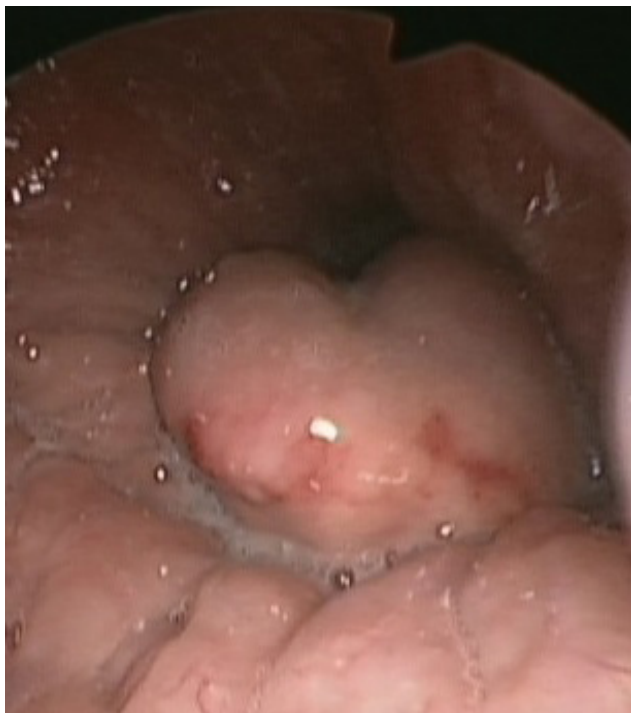

Figure 2: Fibreoptic laryngoscopy revealed a congested epiglottis narrowing the laryngeal inlet.

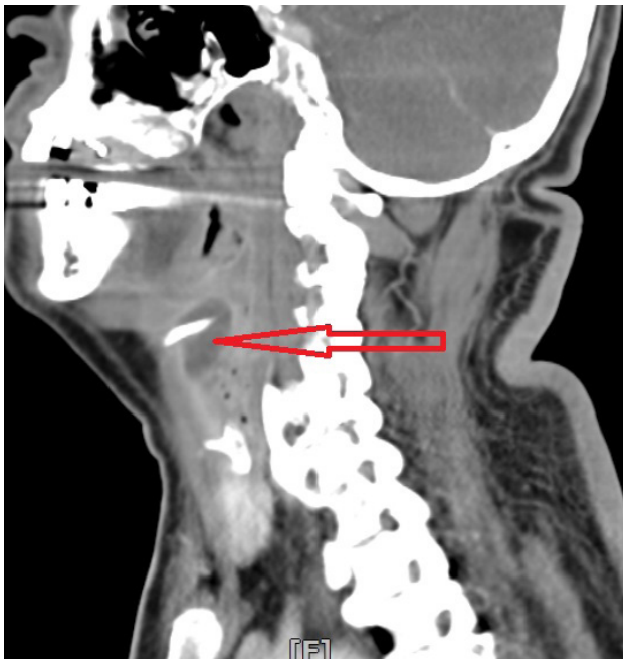
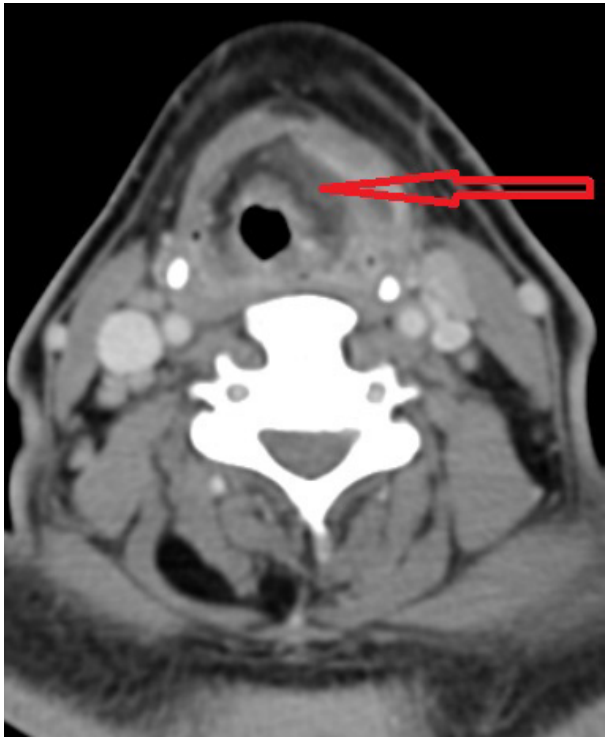

Figure 3: Rim-enhancing hypodense collection area in the epiglottic region in axial (3a) and saggital (3b) views with associated laryngeal edema.

DISCUSSION

Epiglottic abscess is classically considered a disease of children, now becoming a disease of adults, predominantly of middle age and the male sex.⁴ The most common organisms to cause the disease is *Haemophilus influenzae type B* (Hib) in children. In adults Hib were found in only 20% of cases.⁵ Common organisms in adult include *Beta-hemolytic Streptococcus group A or C*, *Streptococcus pneumoniae*, *Staphylococcus aureus* and *Hemophilus parainfluenza virus*, *Herpes simplex virus*, *Epstein-Barr virus* and *parainfluenza virus*. Other causes include direct trauma, thermal and more commonly found in the immunocompromised state.

The clinical features of acute epiglottitis and epiglottic abscess are same, owing to the nature of the conditions which affect the same structure. In adults, odynophagia and unable to swallow saliva are the two main complaints, which can be found in more than 80% of patients.² Other symptoms include fever, hoarseness, dyspnea, stridor and muffled voice.

Lateral soft-tissue neck radiograph is the main investigation tool to diagnose acute epiglottitis. There is no difference in the findings of an acute epiglottic abscess. The classical thumb sign is the pathognomonic features of it. The sign is a shadow of the swollen globular epiglottis. It is quick, safe and reliable way to diagnose epiglottitis as compared to other investigation tools.

Examination of the larynx either with indirect laryngoscopy mirror or rigid laryngoscope should be performed with great precaution in order to avoid laryngeal spasm. It only should be performed by the trained personel with a tracheostomy and intubation sets ready. The use of flexible laryngoscopy is safer as the view can be obtained while maintaining a distance between the tip of the scope with the laryngeal inlet. Laryngoscopic view of the swollen epiglottis provides more accurate information for the diagnosis, where the 'red cherry' appearance of the structure can be appreciated. Computed tomography or MRI is not routinely recommended to establish the initial diagnosis, but may be necessary to exclude complications.³

There is difference between early prophylactic intubation and selective intubation in cases of acute epiglottitis. Early prophylactic intervention is safest and preferred in children however the it is associated with greater morbidity and longer hospitalization periods.⁷ On the contrary, an adult would benefit from selective intubation whereby they will be treated conservatively first. The danger of both is that the epiglottic swelling may get ruptured and hemorrhage and abscess may get aspirated. Fibreoptic nasal intubation is one of the ways to overcome this complication.

Once the diagnosis is established, treatment which consists of parenteral antibiotics, corticosteroids, adrenaline inhalations and humidified air can be commenced. Surgical intervention is indicated when the infection progresses into suppuration and collection.⁶

In conclusion, epiglottic abscess is a rare sequelae of acute epiglottitis. A high index of suspicion should be kept especially in a non-resolving acute epiglottitis after conservative medical treatment. Airway intervention is the most important and low threshold for airway intubation should be applied. Accurate diagnosis and appropriate treatment should be instituted in minimizing mortality in adults.

REFERENCES

1. Salman R, Lateef M, Qazi SM, Rafiq S. Adult epiglottic abscess: A case report. *Indian J Otolaryngol Head Neck Surg* 2011;63(Suppl. 1):85–6.
2. Wick F, Ballmer PE, Haller A. Acute epiglottitis in adults. *Swiss Med Wkly* 2002;132(37-38):541–7.
3. Chung CH. Case and literature review: adult acute epiglottitis – rising incidence or increasing awareness? *Hong Kong Journal of Emergency Medicine* 2001;8(4):227-31.
4. Frantz TD, Rasgon BM, Quesenberry CP Jr. Acute epiglottitis in adults: analysis of 129 Cases. *JAMA* 1994;272(17):1358-60.
5. Trollfors B, Nylen O, Carenflet C et al. Aetiology of acute epiglottitis in adults. *Scand J Infect Dis* 1998;30(1):49–51.
6. Berger G, Landau T, Berger S, Finkelstein Y, Bernheim J, Ophir D. The rising incidence of adult acute epiglottitis and epiglottic abscess. *Am J Otolaryngol* 2003;24(6):374-83.
7. Park KW, Darvish A, Lowenstein E. Airway management for adult patients with acute epiglottitis. *Anesthesiology* 1998;88(1):254-61.