

Case Report

A "Near Miss" Congenital Eventration of the Right Hemidiaphragm in A Neonate: A Case Report

*Zurina Zainudin¹, Farah Inaz Syed Abdullah², Neoh Siew Hong², Mughni Bahari³, Irene Cheah Guat Sim²

¹Department of Paediatric, Faculty of Medicine and Health Sciences, University Putra Malaysia, 43400 Serdang, Selangor, Malaysia.

²Neonatology Unit, Pediatric Institute, Hospital Kuala Lumpur, Jalan Pahang, 50586 Wilayah Persekutuan Kuala Lumpur, Malaysia.

³Paediatric Surgical Unit, Pediatric Institute, Hospital Kuala Lumpur, Jalan Pahang, 50586 Wilayah Persekutuan Kuala Lumpur, Malaysia.

ABSTRACT

Focal eventration involving the posterior segment of the hemidiaphragm is a rare congenital anomaly. We report of a 10-day-old infant who presented with significant respiratory insufficiency and failure to show any responses to standard treatment. The diagnosis of focal eventration of the diaphragm was not anticipated until ultrasonographic examination revealed the defect. Diaphragmatic plication resulted in complete resolution of symptoms. A high level clinical awareness is crucial as a relatively simple surgical procedure could avert long term life-threatening complications.

Keywords: Infant, Congenital diaphragmatic eventration, Respiratory insufficiency

INTRODUCTION

Diaphragmatic eventration is a rare congenital anomaly caused by an anatomical or functional deficiency of muscular portion of the hemidiaphragm (1). Complete eventration invariably occurs on the left but focal eventration occurs virtually on the right hemidiaphragm predominantly involving the anterior segment (2). Although there are several case series of diaphragmatic eventration, defect localised to the posterior segment of the right hemidiaphragm in neonate has never been highlighted before (2-5). We describe here a "near miss" case of eventration confined to the posterior segment of the right hemidiaphragm associated with absence of classical findings of an abnormal elevation of the dome of diaphragm typically observed on chest radiograph. This is to our knowledge the first such case to be reported.

CASE HISTORY

A 10-day-old baby boy was seen at a local health clinic for worsening respiratory distress. He was noted to have rapid breathing especially during feeding since discharged from the hospital after delivery. There was no history of fever, cough,

choking episode or history of contact with sick person. He was born at term via emergency caesarean section for fetal distress with birth weight of 3400gm. Apgar score was 9 and 10 at 1 and 5 minutes respectively. The mother had history of leaking amniotic fluid prior to delivery with no other history suggestive of chorioamnionitis.

On examination, he was afebrile, active and thriving well. He had respiratory rate of 65 breaths/minute with prominent intercostal and subcostal recessions. His oxygen saturation ranged between 90% and 93% on room air. His pulse rate was 125 beats/minute and blood pressure was 79/55mmHg. Chest examination revealed reduced breath sound localised to the lower half of the right lung. Other systemic examination was unremarkable.

Chest radiograph showed an area of homogenous opacity in the mid and lower zone of the right lung with a well-defined right hemidiaphragm and right heart border (Figure 1). Haematological indices and acute phase proteins were within normal limit (total white cell count 12,790/ μ L with 37.5% neutrophils, 46.1% lymphocytes, platelet 302,000/mm³ and C-reactive protein 0.3mg/dL). Blood culture was sterile for bacterial growth and nasopharyngeal aspirate was negative for respiratory viruses. Echocardiographic examination revealed normal structural heart.

An initial clinical impression of community acquired pneumonia was entertained. He was commenced on nasal continuous positive airway pressure for respiratory support in addition to intravenous crystalline penicillin and gentamycin. Syrup erythromycin was later added to the therapy for suspicion of an atypical infection.

However symptoms persisted and a repeat chest radiograph revealed no resolution of the opacity after two weeks of antimicrobial therapy; hence warranted for further evaluation.

*Corresponding Author: Zurina Zainudin
zaizurina@upm.edu.my

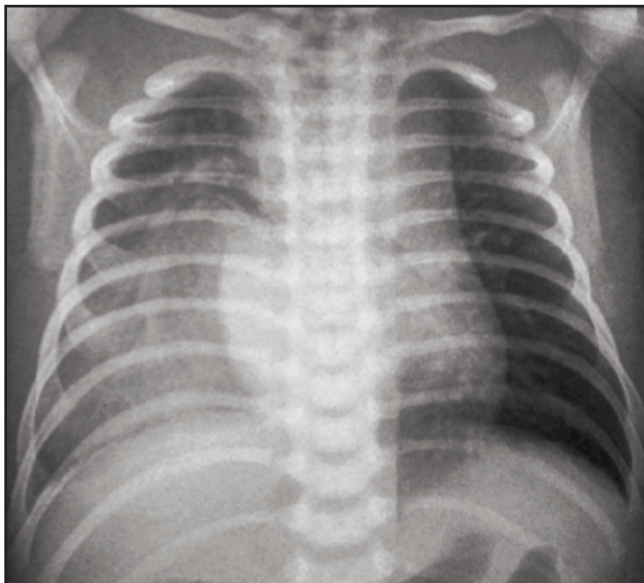


Figure 1: Chest radiograph showed an area of homogenous opacity in the mid and lower zone of the right lung with intact right heart border and right hemidiaphragm.

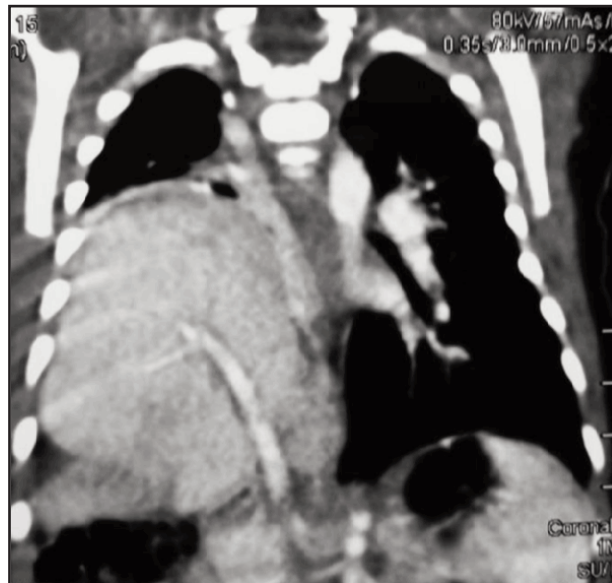


Figure 2: Contrast enhanced computed tomography of the thorax (CECT thorax) showed presence of liver parenchyma in the right thoracic cavity predominantly at the posterior aspect with intact anterior and posterior hemidiaphragm.

The subsequent ultrasonographic study disclosed the presence of liver parenchyma in the right thoracic cavity predominantly at the posterior aspect with intact anterior and posterior right hemidiaphragm suggestive of focal eventration. These findings were supported by a contrast enhanced computed tomography of the thorax (Figure 2). He made a tremendous recovery following diaphragmatic plication and was successfully weaned off oxygen 4 days post-operatively. He continued to do well on follow up.

DISCUSSION

Congenital diaphragmatic eventration is a rare anomaly occurring in 1 out of 10,000 live births (2). It results from failure of the fetal diaphragm to muscularise completely during embryonic development and is replaced by fibroelastic tissue (1). It typically involves either the entire or a segment of hemidiaphragm and is usually unilateral. The defect is commonly seen on the left hemidiaphragm (2). Congenital eventration localised to the posterior segment of right hemidiaphragm is rarely reported.

Diaphragmatic eventration may be associated with upward migration of abdominal viscera and might affect lung development to a varying degree. Inefficient contraction of the affected hemidiaphragm during breathing also contributes to significant alteration in the respiratory physiology including atelectasis and lung collapse. These account for the predominant respiratory symptoms in the presenting complaint. However it has not been associated with pulmonary hypoplasia as in the case of congenital diaphragmatic hernia (1). A small percentage of patients present with symptoms related to gastrointestinal tract

including abdominal pain and vomiting. In some, it remains asymptomatic and the diagnosis is discovered incidentally in normal screening of chest radiograph (3).

A localised bulge or generalized elevation of the diaphragm on chest radiograph is the classical characteristic of eventration (1-3). This entity can be distinguished from diaphragmatic hernia as the diaphragm retains its continuity and attachments to the costal margin is undisrupted. In contrast, defect localised to the posterior segment of the right hemidiaphragm often presents as an opacity mimicking a consolidation or a mass lesion without the distinctive evidence of elevated diaphragmatic contour on chest radiographs resulting in an unanticipated diagnosis as illustrated in our patient. Ultrasonography is proven to be beneficial in providing valuable information on the integrity of the diaphragm with content of the eventration and highlights the other diaphragmatic pathologies (3). Fluoroscopy is another imaging tool that is useful to evaluate diaphragmatic dome movement. However this modality is less favourable as it has the disadvantage of exposing patients to ionizing radiation. In cases where the diagnosis still remains in doubt, computed tomography or magnetic resonance imaging may be performed as an adjunct technique to aid diagnosis (3).

Diaphragmatic plication is a standard and well described technique to restore normal pulmonary parenchymal volume and symptom relief. Indications for surgical repair include failure to wean from respiratory support and recurrent chest infections (4,5). A minimally invasive thoracoscopic or laparoscopic surgery is the most recent approach of operative treatment (5). This newer technique had been shown to be safe, efficient and associated with less postoperative morbidity.

CONCLUSION

This case illustrates a typical manifestation of focal eventration involving the posterior segment of right hemidiaphragm. This diagnosis should be strongly considered in cases of respiratory distress in neonates with normal diaphragmatic appearance on chest radiograph especially in the absence of fever and other symptoms of infection. A high level of clinical awareness is crucial as a relatively simple surgical procedure like diaphragmatic plication can save life and avert long term life-threatening complications.

ACKNOWLEDGEMENT

We thank all the staffs of Neonatal Unit of Kuala Lumpur Hospital for their assistance in the management of our patient. We also wish to thank the Paediatric Surgical Team of Paediatric Institute Kuala Lumpur Hospital for their contributions to the management of our patient.

REFERENCES

1. Robert MK, Bonita FS, Nina FS, Joseph WSG, Richard EB. Nelson textbook of Pediatrics. 19th edition, Elsevier-Saunders; 2012:597.
2. Soni A, Singh P, Sigh RJ & Sood V. Eventration of Diaphragm – Embryological basis. J Anat Soc India. 2005;54:39-41.
3. Eren S, Ceviz N, Alper F. Congenital diaphragmatic eventration as a cause of anterior mediastinal mass in the children: imaging modalities and literature review. Eur J Radiol 2004 Jul;51(1):85-90.
4. Victoria V Lao, Oliver B Lao, Shahab F Abdessalam. Laparoscopic Transperitoneal Repair of Pediatric Diaphragmatic Eventration using Endostaplr Device. J Laparoendosc Adv Surg Tech A. 2013;23(9):808-13.
5. Sheng de Wu, Na Zang, Jin Zhu, Zhengxia Pan, Chun Wu. Congenital diaphragmatic eventration in children: 12 years' experience with 177 cases in a single institution. Journal of Pediatric Surgery. 2015;50(7):1088-92.